





## 8<sup>TH</sup> CONGRESS OF THE SOCIETY OF ENDOMETRIOSIS AND UTERINE DISORDERS

### ADENOMYOSIS

Kh . Shadjoo

MD

Ob&Gyn

Fellowship of Advanced Laparoscopy (Endometriosis)

Avicenna Endometriosis Clinic

پژوهشگاه ابن سینا





# The Impact of Laparoscopic Surgery for Endometriosis on Patients Symptoms

Khadijeh Shadjoo<sup>1\*</sup>, Fatemeh-Sadat Hosseini-Mazinani<sup>2</sup>, Maryam Tajik<sup>1,3</sup>, Razieh Saber-Shahraki<sup>1</sup>

1) Reproductive Biotechnology Research Center, Avicenna Research Institute, ACECR, Tehran, Iran  
2) Department of Stem Cells & Developmental Biology, Cell Science Research Center, Royan Institute for Stem Cell Biology and Technology, ACECR, Tehran, Iran  
3) Department of Reproductive Health & Midwifery, Faculty of Medical Sciences, Tarbiat Modares University, Tehran, Iran  
\* Correspondence: drshadjoo@gmail.com

## Background

Endometriosis is a chronic benign gynecological disease that unfortunately impairs the quality of life of affected women. Laparoscopy is the most common surgical procedure for diagnosing and treating endometriosis as that relieves the associated painful symptoms in most cases. However, it does not make it clear how long the therapeutic benefits would last. The aim of this study was to evaluate pain relief after laparoscopic removal of endometriosis over a 2-year period of postoperative follow-up.

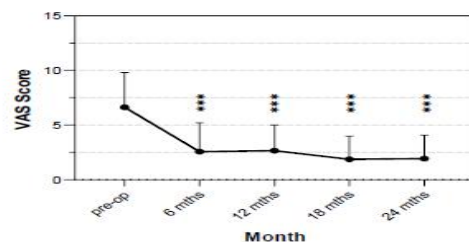
## Methods

A population-based registry study included one hundred and twenty-two symptomatic women with endometriosis who underwent laparoscopic surgery for endometriosis between 2019–2021. Prior to surgery, a visual analog scale was used to assess pain intensity, as well as after 6, 12, 18, and 24 months after surgery.

## Results

The mean visual analog scale score for dysmenorrhea decreased from  $6.6 \pm 3.1$  at baseline to  $2.5 \pm 2.6$  at 6 month ( $p < 0.001$ ),  $2.6 \pm 2.3$  ( $p < 0.001$ ) at 12 month,  $1.8 \pm 2.1$  ( $p < 0.001$ ) at 18 month, and  $1.9 \pm 2.1$  ( $p < 0.001$ ) at 24-month post operation.

Figure 1. Dysmenorrhea visual analog scale (VAS) scores significantly improved after surgery.



Before surgery, mean visual analog scale score for dyspareunia was  $3.4 \pm 3.7$ , but decreased to  $1.9 \pm 2.4$  after 6-month ( $p < 0.01$ ),  $1.5 \pm 2.1$  after 12-month ( $p < 0.01$ ),  $1.3 \pm 2.02$  after 18-month ( $p < 0.001$ ), and  $2.1 \pm 2.6$  after 24-month ( $p < 0.005$ ) post surgery. The mean visual analog scale score for noncyclic pelvic pain showed reductions after 6 months ( $2.2 \pm 3.7$  to  $1.5 \pm 2.3$ ), although there was a recurrence.

Figure 2. Dyspareunia visual analog scale (VAS) scores significantly improved after surgery.

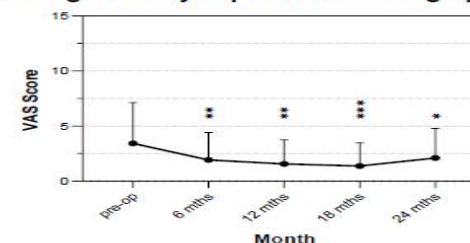


Table 1. Summary of women's symptoms before and after laparoscopic surgery for endometriosis.

	pre-op	6 mths	12 mths	18 mths	24 mths
Quantitative evolution of symptoms (VAS) (Mean ± SD)					
Dysmenorrhea	6.6±3.1 (122)	2.5±2.6*** (of 58)	2.6±2.3*** (of 48)	1.8±2.1*** (of 46)	1.9±2.1*** (of 47)
Dyspareunia	3.4±3.7 (122)	1.9±2.4** (of 58)	1.5±2.1** (of 46)	1.3±2.02** (of 45)	2.1±2.6* (of 46)
Non-cyclic pain	2.2±3.7 (122)	1.5±2.3 (of 58)	2.6±2.8 (of 48)	1.9±2.9 (of 45)	2.2±2.8 (of 45)

\*  $p < 0.05$ , \*\*  $p < 0.01$ , \*\*\*  $p < 0.001$

## Conclusion

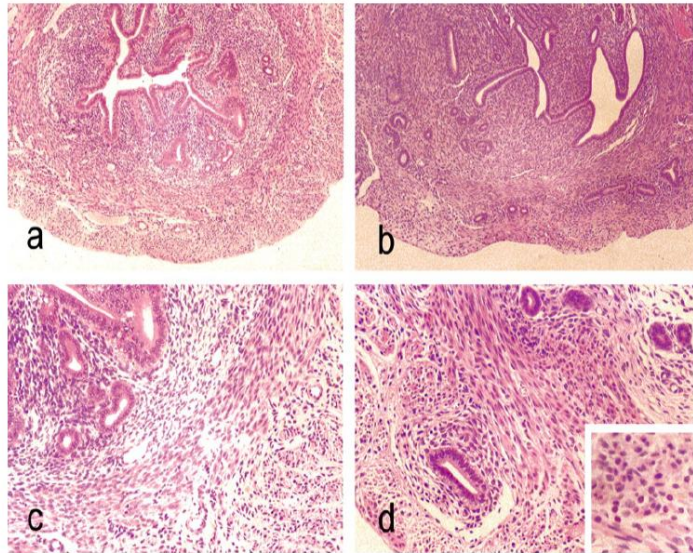
In many women with preoperative symptoms, laparoscopic excision of endometriosis significantly improves dysmenorrhea and dyspareunia for up to 2 years after surgery. Therefore, women with endometriosis who have severe pain complaints may benefit from conservative laparoscopic surgery.

## References

1. Aurelie Comptour, Pauline Chauvet, Michel Canis, Anne-Sophie Gremeau, Jean-Luc Pouly, Benoit Rabichon, Bruno Pereira, Nicolas Bourdel, Patient quality of life and symptoms following surgical treatment for endometriosis. The Journal of Minimally Invasive Gynecology (2018).
2. Busacca M, Bianchi S, Agnoli B, Candiani M, Calla C, De Marinis S, Vignali M. Follow-up of laparoscopic treatment of stage III-IV endometriosis. J Am Assoc Gynecol Laparosc. 1999 Feb;6(1):55-8. doi: 10.1016/s1074-3804(99)80041-3. PMID: 9971852.

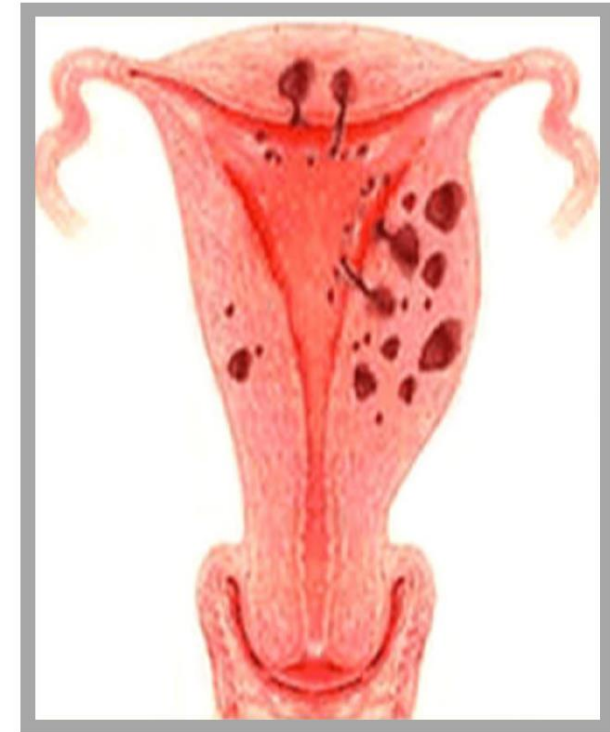


# Adenomyosis: Definition



## Histological definition:

Presence of endometrial glands and/or stroma outside the uterine cavity



## Two distinct histologic types:

- **Diffuse Adosis +++++** The invasion of endometrial glands and/or stroma within the myometrium
- **Focal Adosis or Adenomyomata:** circumscribed tumors made up of endometrium and muscle tissue

# Prevalence

Ranges from 5 to 70%

- ▶ This high variability depends on several Factors:
  - ❑ diagnostic criteria
  - ❑ characteristics of the sample analyzed
  - ❑ investigator's skills
- ▶ The incidence of the disease is higher in multiparous women

# Prevalence

- ▶ variant of endometriosis
- ▶ Approximately(  $1/3$ )one third of patients with endometriosis are affected by adenomyosis

# Impact on women in reproductive age

- ❑ Dysmenorrhea
- ❑ Metrorrhagia
- ❑ Chronic pelvic pain
- ❑ Dyspareunia
- ❑ Infertility often occur
- ❑ third of the women is asymptomatic

# Relationship between endometriosis *and* adenomyosis

Adenomyosis: MRI definition

Junctional Zone (JZ)  $\geq 12$  mm

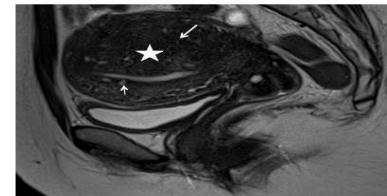
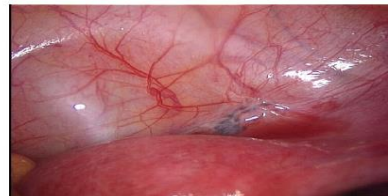and

Ratio JZ / Myometrium  $> 40\%$

E  
N  
D  
O  
M  
E  
T  
R  
I  
O  
S  
I  
S

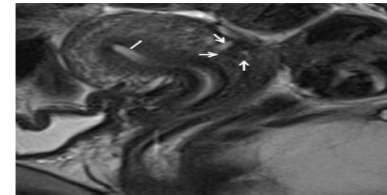
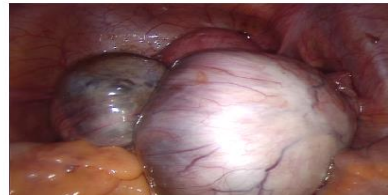A  
D  
E  
N  
O  
M  
Y  
O  
S  
I  
S

SUP



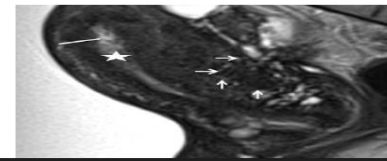
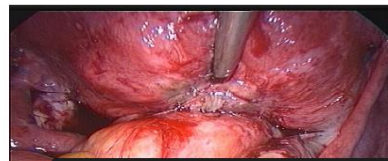Diffuse

OMA



Focal

DIE

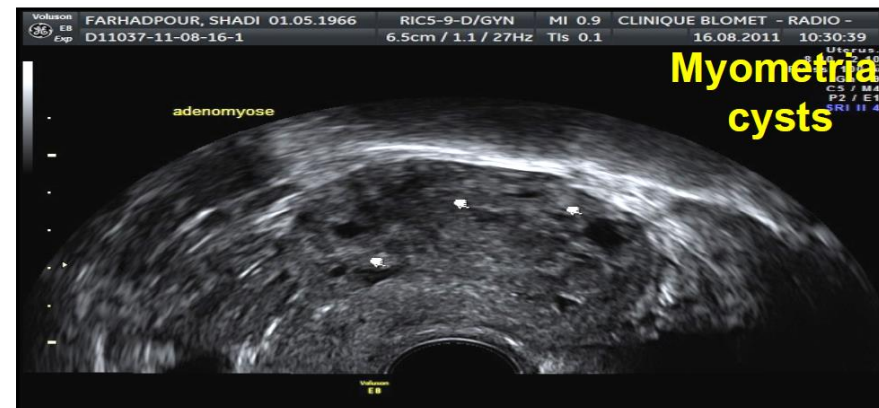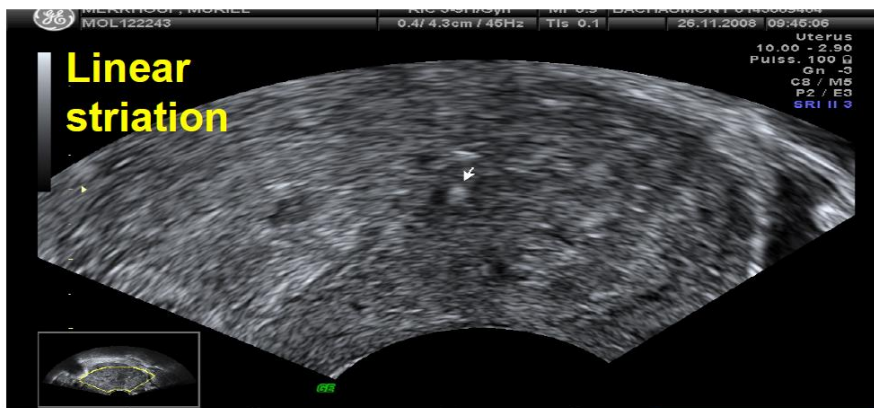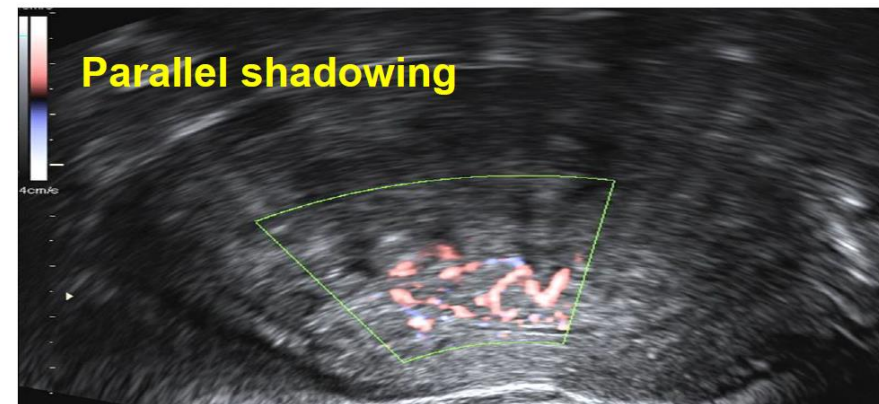
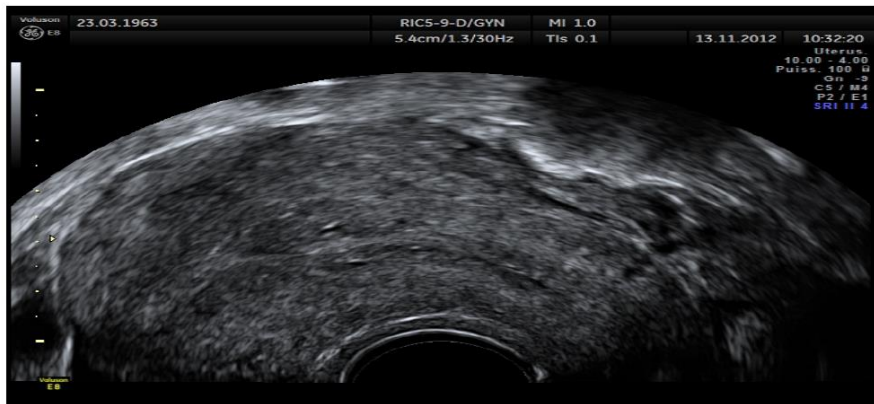


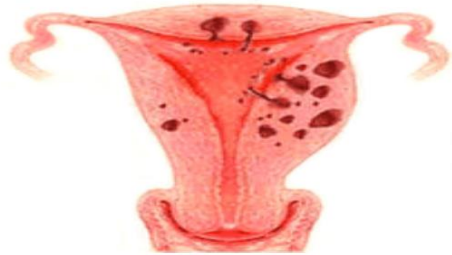Diffuse  
and  
Focal



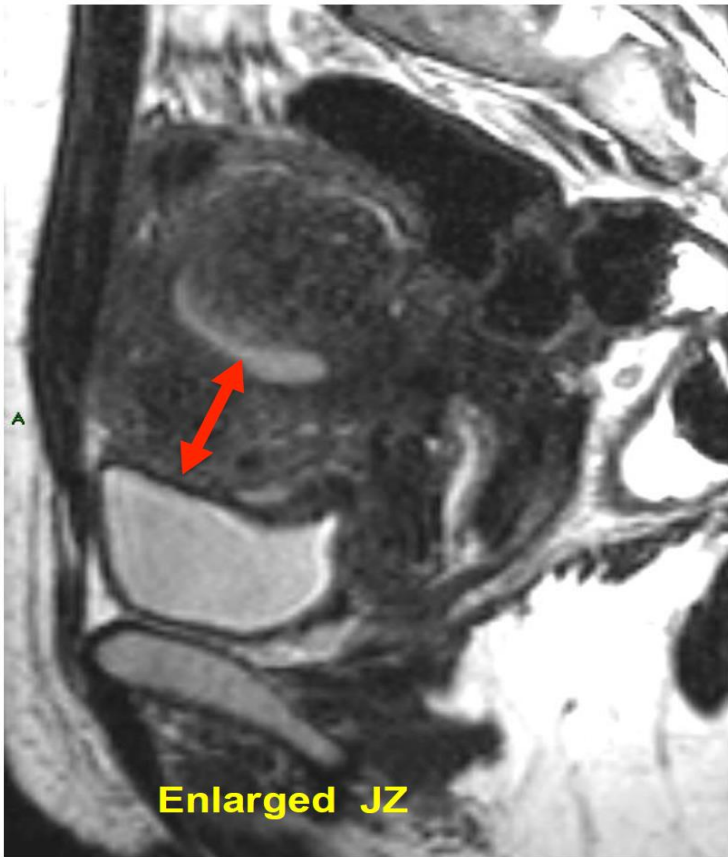
# Adenomyosis: TV Sonographic signs

Globular uterus and asymmetrical myometrial thickening  
not caused by the presence of fibroids

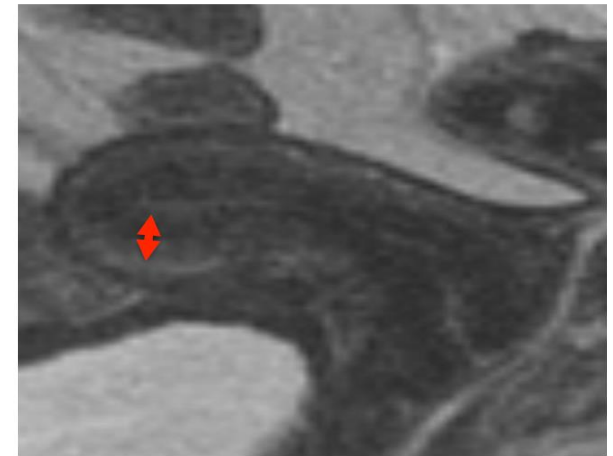




# Adenomyosis: MRI



- High signal - intensity myometrial spots
- Visible Junctional Zone with a threshold value  $> 12$  mm
- Presence of an ill-defined-low-signal intensity area of myometrium
- Ratio ZJ/Myometrium  $> 40\%$



Normal Junctional Zone

Combination of these 3 criteria:  
accuracy of 85.5%

# Adenomyosis treatment

1-Medical

2-Excisional

3-Nonexcisional



# Determining factors for selection of type of treatment

- Age
- Desire for future pregnancy
- Symptoms
- Coexisting pelvic disease

# Medical Therapies

- Oral contraceptive pills
- Progestins
- Selective oestrogen receptor modulators
- Selective progesterone receptor modulators
- Levonorgestrel-releasing intrauterine device
- Aromatase inhibitors
- Danazol
- Gonadotrophin receptor hormone agonists
- NSAIDS

# Surgical Treatment



## 1-Hystrectomy

standard treatment for symptomatic adenomyosis



in patients who do not desire future pregnancy

subtotal hysterectomy should avoided(recurrence)

## 2-Uterine sparing surgery

a- excisional

b-non exisional

who refuse hystrectomy



wish to pursue future pregnancy

- preservation of at least 1-1.5 cm of myometrial thickness



# Non-excisional Procedures

- 1- Laparoscopic electrocoagulation
- 2- Laparoscopic uterine a. ligation
- 3- Ablation of focal adenomyosis with HIFUS (high frequency ultrasound)
- 4- Alcohol instillation under sono guide for focal adenomyosis
- 5- Radiofrequency ablation for focal adenomyosis
- 6- Balloon thermoablation
- 7- Uterine a. embolization  
*improvement of dysmenorrhea: 54-84%*  
*improvement of menorrhagia: 50-68%*

# Uterine Artery Embolization

Four groups were evaluated:

- 1- short-term (< 12 months) pure adenomyosis,
- 2- short-term adenomyosis with fibroids (combined adenomyosis)
- 3- long-term (> 12 months) pure adenomyosis
- 4- long-term combined adenomyosis.

Improvement of symptoms occurred in 83.1% (872/1,049) of patients.

**symptom improvement and uterine volume reduction** in patients with adenomyosis are encouraging.

Uterine Artery Embolization for the Treatment of Adenomyosis: A Systematic Review and Meta-Analysis. De brujin et al.evidence-based review 2017

# HIFUS (High-intensity focused ultrasound )

Eleven(11) articles:

1,150 treatments and follow-up data from 990 patients

High-intensity focused ultrasound :

effective and safe in the management of :

symptomatic adenomyosis

can be considered as an alternative uterine-sparing

option for women with this condition.



# Radiofrequency Ablation (RF)

Ultrasound-guided RFA might be a **safe and effective**  
**minimally invasive alternative** in the treatment of  
symptomatic adenomyosis.

Ultrasound-guided transcervical radiofrequency ablation for symptomatic uterine adenomyosis .ning hai etal.Br J Radiol 2017

# Excisional Methods:

- ❖ - Adenomyomectomy
- ❖ (for focal & cystic adenomyosis)
  
- ❖ - myometrectomy or cytoreductive surgery
- ❖ (for diffuse adenomyosis)

Risk of uterine rupture during pregnancy should be discussed with patients

surgery in endometriosis-oliveria et al.Archives of gynecology and obstetrics2017

# Three Principles to Preserve Fertility After Surgery

## First

- ❖ the uterine cavity should be reconstructed
- ❖ *to maintain an intact shape and function*

## Second

- ❖ the fallopian tubes should not be damaged

## Third

- ❖ the uterine wall should be sturdily reconstructed
- ❖ *Suturing should be performed meticulously so that no dead space is created during the reconstruction process*



# Adenomyomectomy

Focal adenomyosis or adenomyoma is separated from the normal myometrium and excised

Adenomyomectomy was first introduced by Hyams in 1952.

# Myometrectomy(cytoreductive surgery)

Treatment of diffuse/severe adenomyosis

Removing as much of the macroscopic lesion as possible

Sometimes it is not possible to remove all the disease and the surgery is considered cytoreductive only.

*Classical technique:*

*the steps are like an abdominal myomectomy*

*A transverse or vertical uterine incision is applied, then adenomyotic tissue is resected*

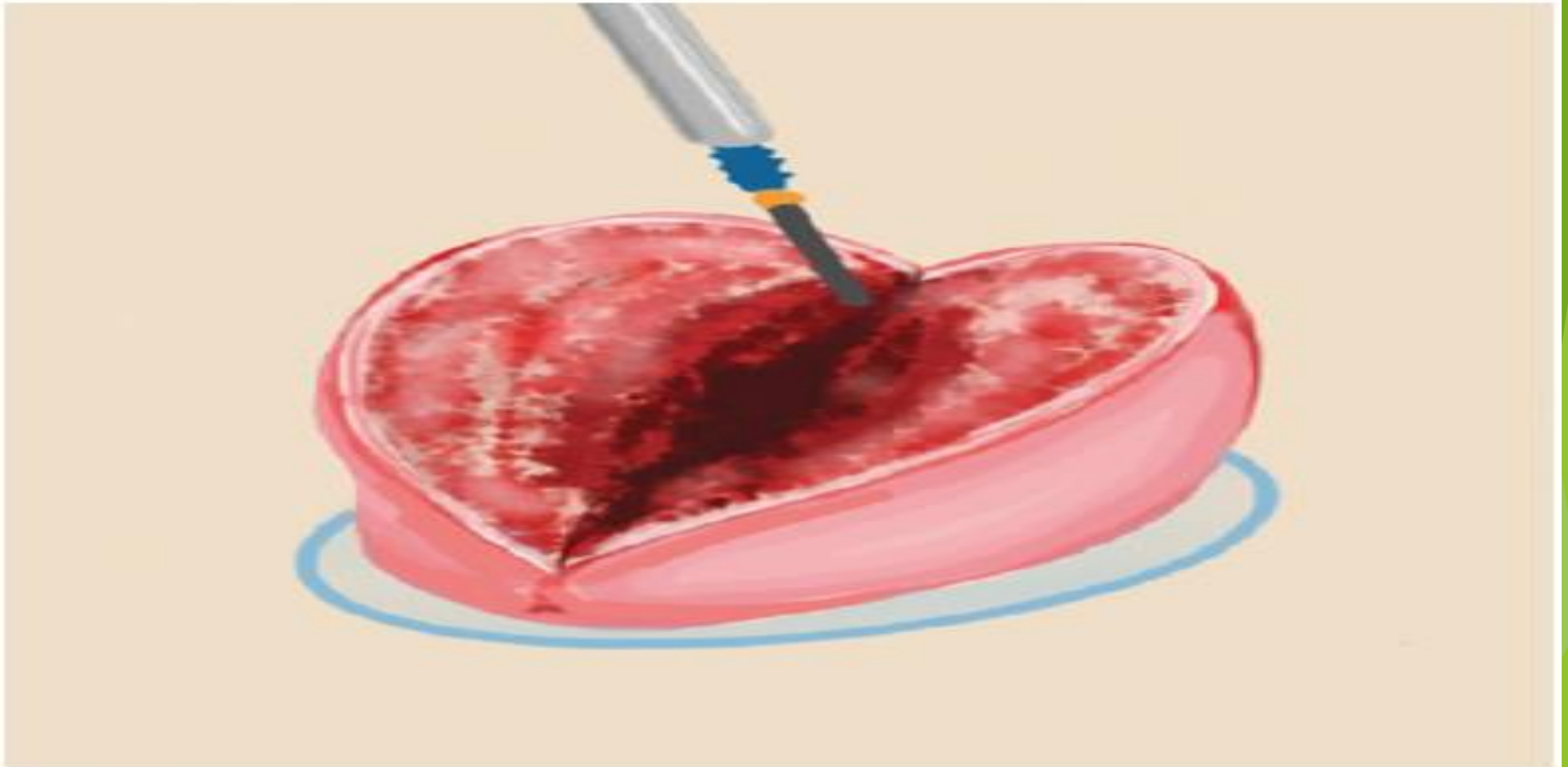
*the uterine wall is inspected for macroscopic adenomyotic lesions*

*Uterine closure is done by two or three layers of suturing by interrupted technique*

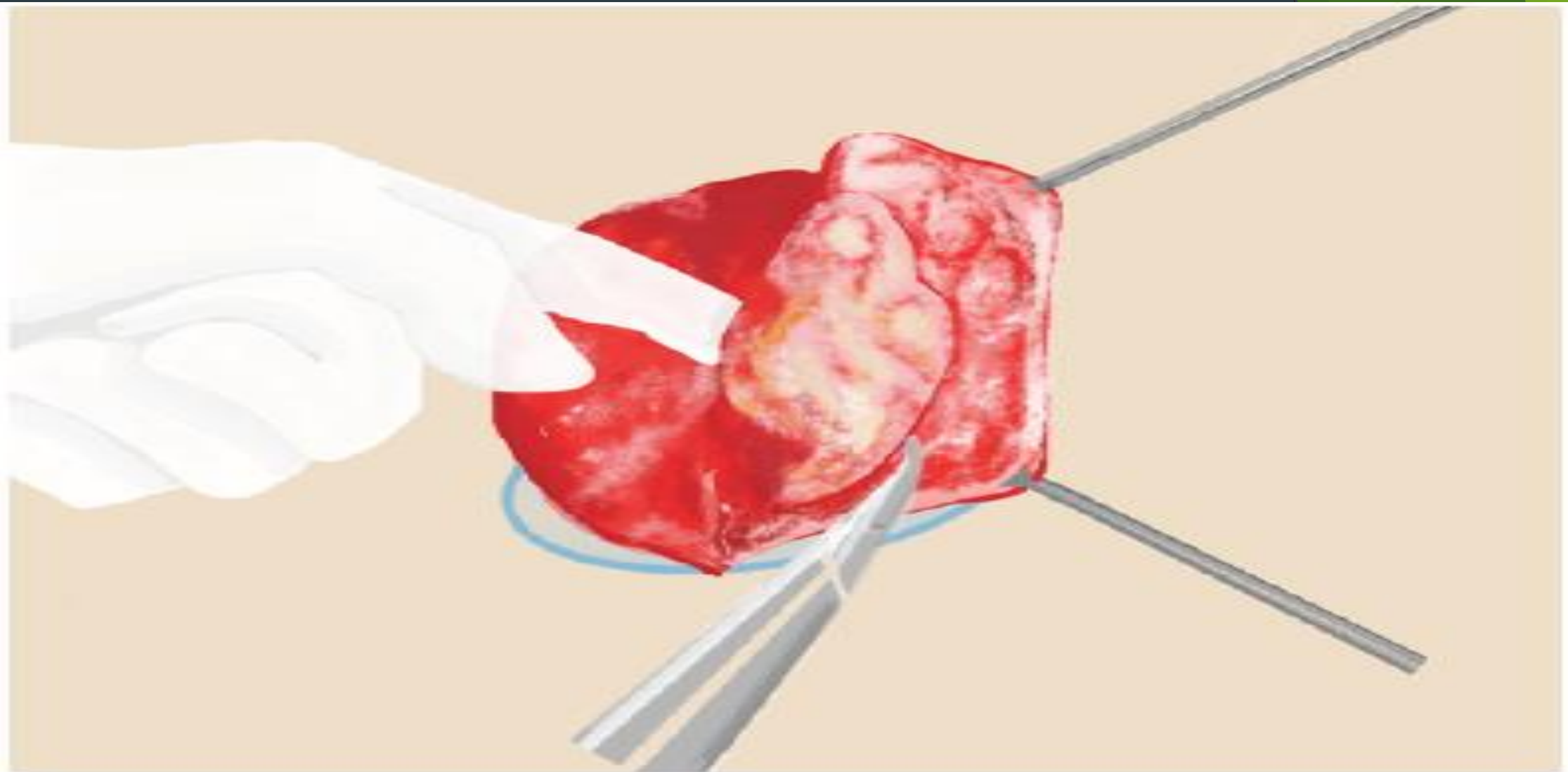
*Hematoma should be prevented.*

# Laparoscopic assisted adenomyomectomy (double flap method)

- Nine cases were analyzed
- The average patient age was 37.0 years
- average follow-up duration was 32.8 months
- All patients showed improvement in dysmenorrhea and hypermenorrhea after surgery
- Adenomyosis was progressed in the side opposite the site of operation
- One patient required a total laparoscopic hysterectomy 27 months after surgery.

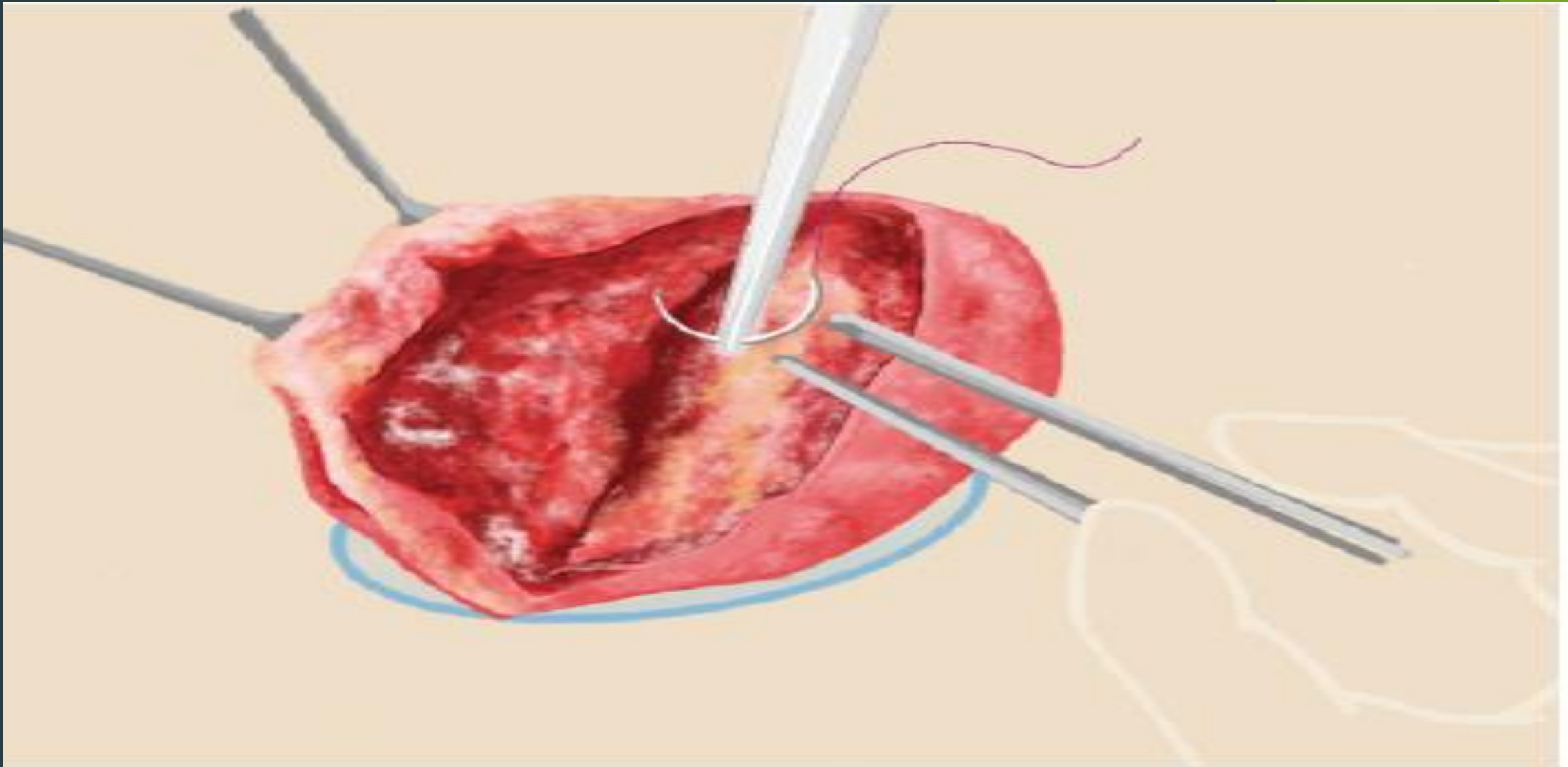


**Fig. 1.** Uterine wall incision from fundus to upper cervical margin: endometrial cavity should be exposed.

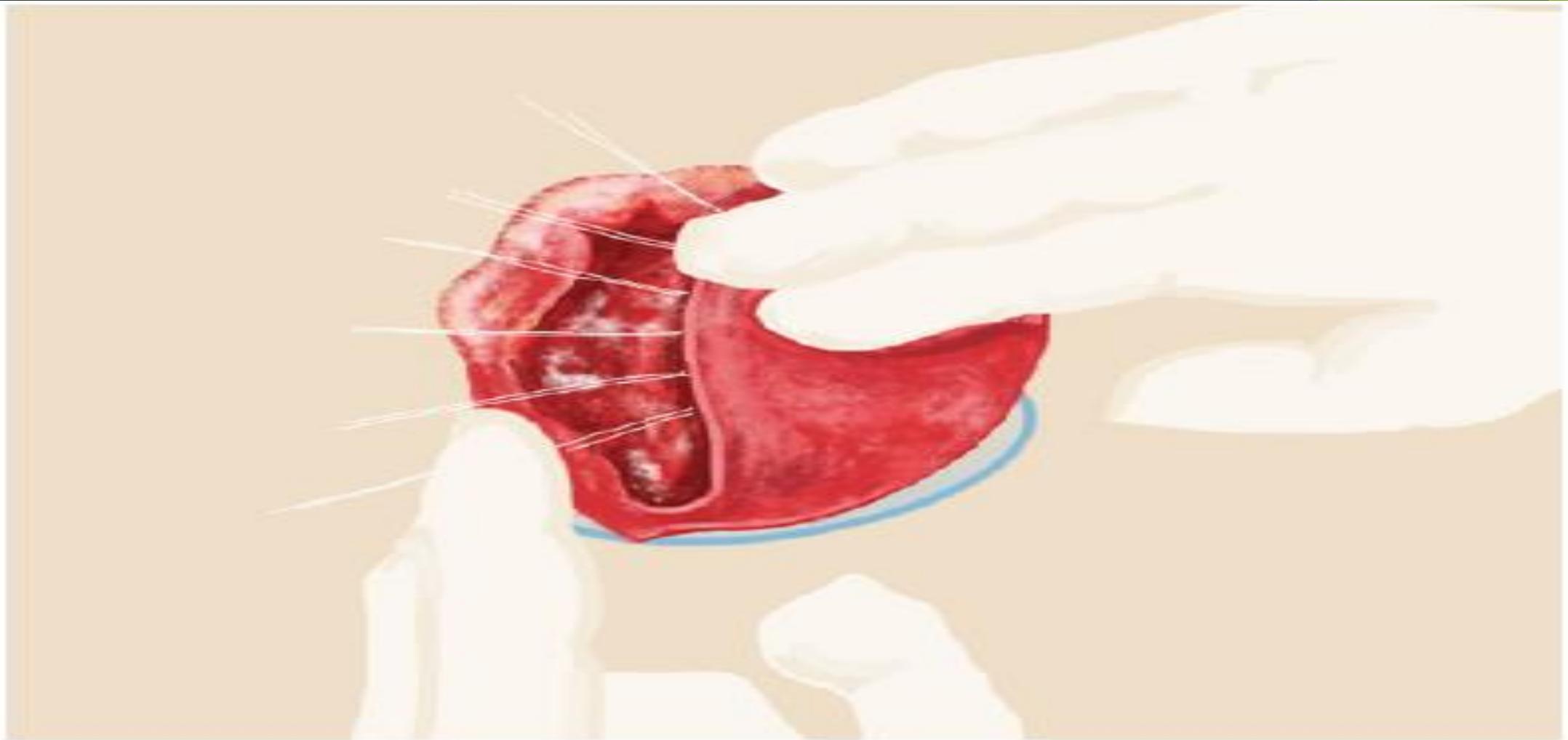


**Fig. 2.** Removal of adenomyotic tissue using scapel, metzenbaum or monopolor cutting: myometrial tissue should be preserved 0.5 to 1.0 cm in thickness above the endometrial cavity and below the serosal layer.

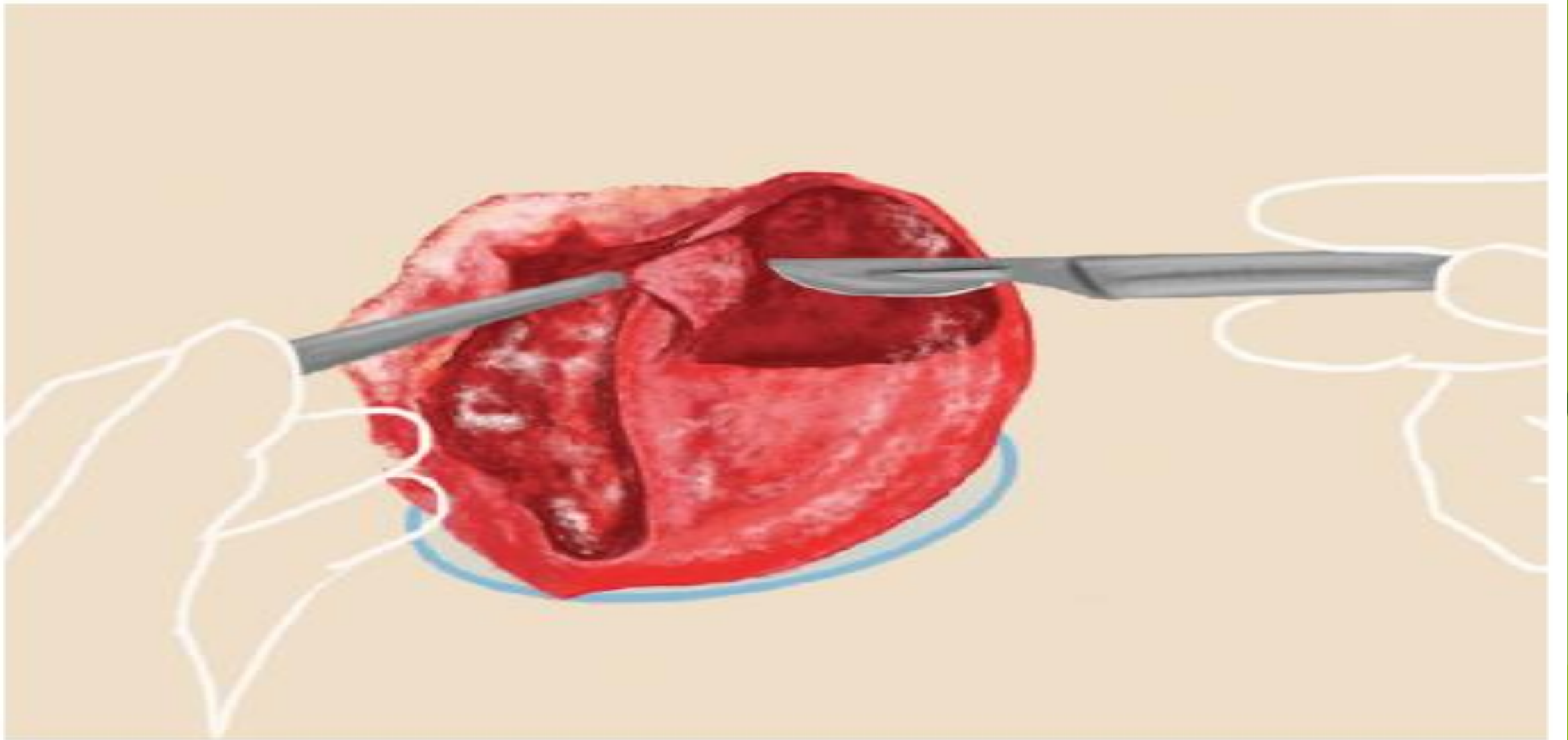




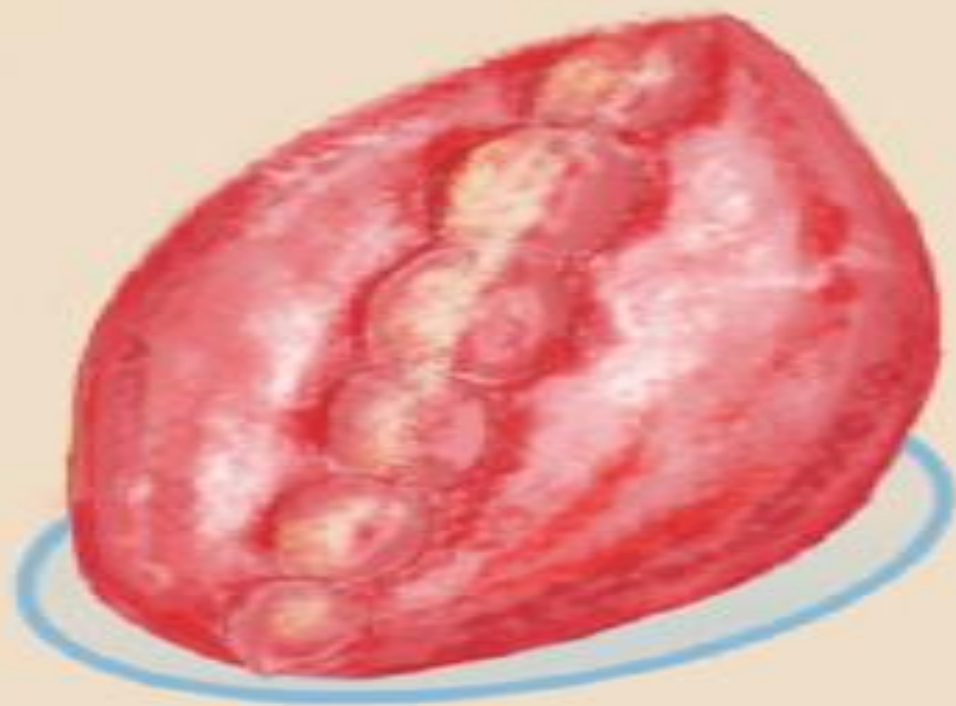
**Fig. 3.** Repair of endometrial cavity using 2-0 vicryl interrupted suture.



**Fig. 4.** Covering the first flap using one side serosal layer by 2-0 vicryl interrupted suture: careful suture is needed to prevent dead space or hematoma between the tissues.



**Fig. 5.** Serosal layer of the first flap must be removed before covering the second flap.



**Fig. 6.** Covering the second flap using the other side serosal layer by 2-0 vicryl interrupted suture.

# Nishida method

## Laparotomic technique

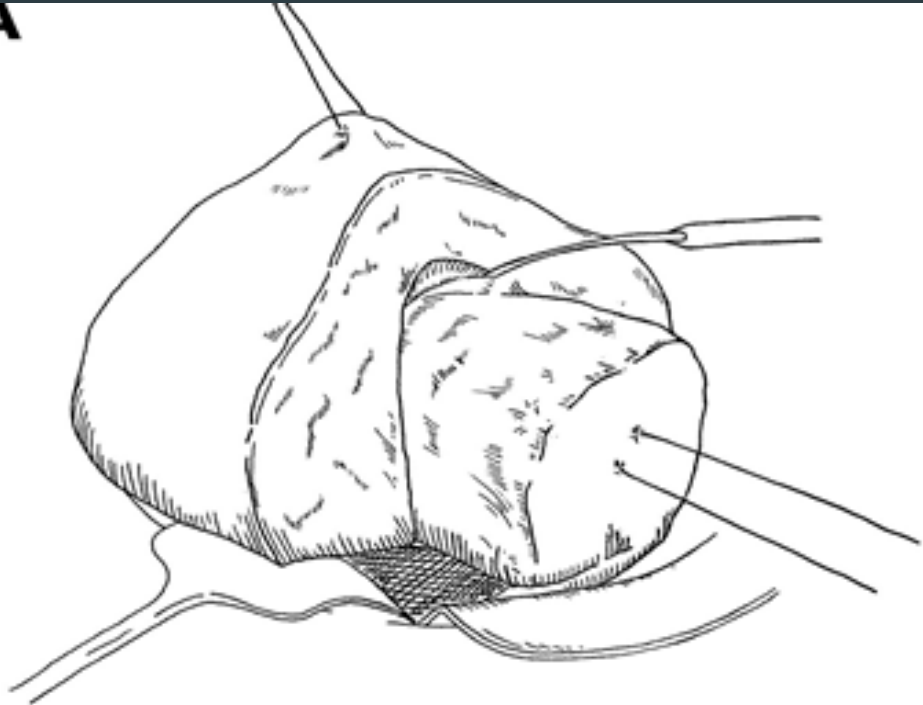
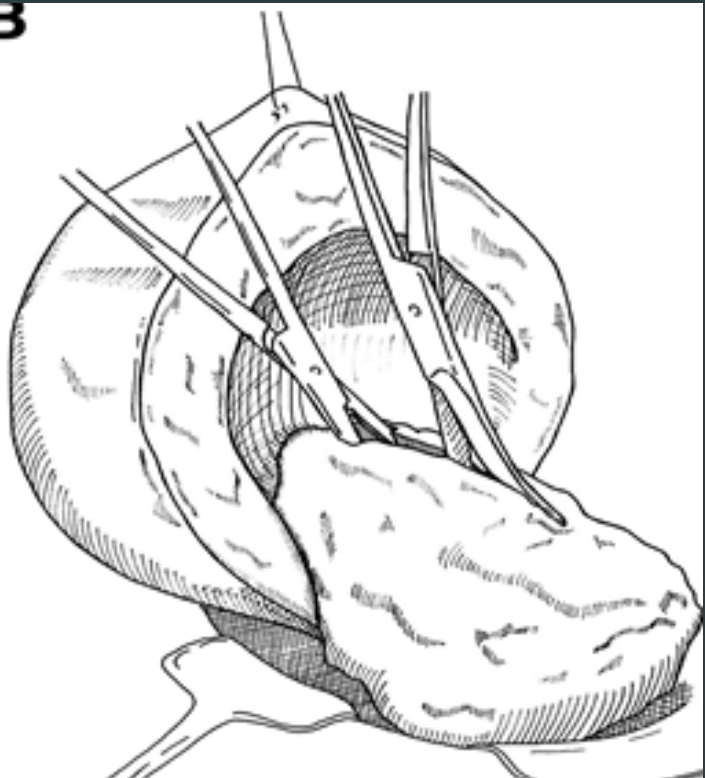
- 1-diluted vasopressin injection
- 2-uterine fundus was transected longitudinally to divide inside and outside
- 3-An asymmetric dissection of the uterus was performed preserving both the uterine cavity and the uterine arteries.
- 4-the myometrium was dissected diagonally
- 5-transverse incision was made to open the uterine cavity
- 6-the adenomyotic lesion was excised using a loop electrode to a thickness of 5 mm of the inner myometrium. The procedure continues with excision of adenomyosis to a thickness of 5 mm of the serosal myometrium
- 7-Endometrial cavity was then closed
- 8-the uterine flaps were rejoined in layers.

## Nishida :

the mean VAS score of dysmenorrhea decreased from 9.4 to 0.8  
anemia due to menorrhagia improved in all women

Two patients became pregnant



**A****B**

# Osada Method (Triple-flap Method)

laparotomic technique

the treatment of the severe diffuse form of the disease

**the “triple-flap method”**

radical excision of adenomyosis

(leaving 1 cm margin of tissue above the endometrium and 1 cm margin of tissue below the serosal surface)

with subsequent triple-flap reconstruction of the uterus

104 women

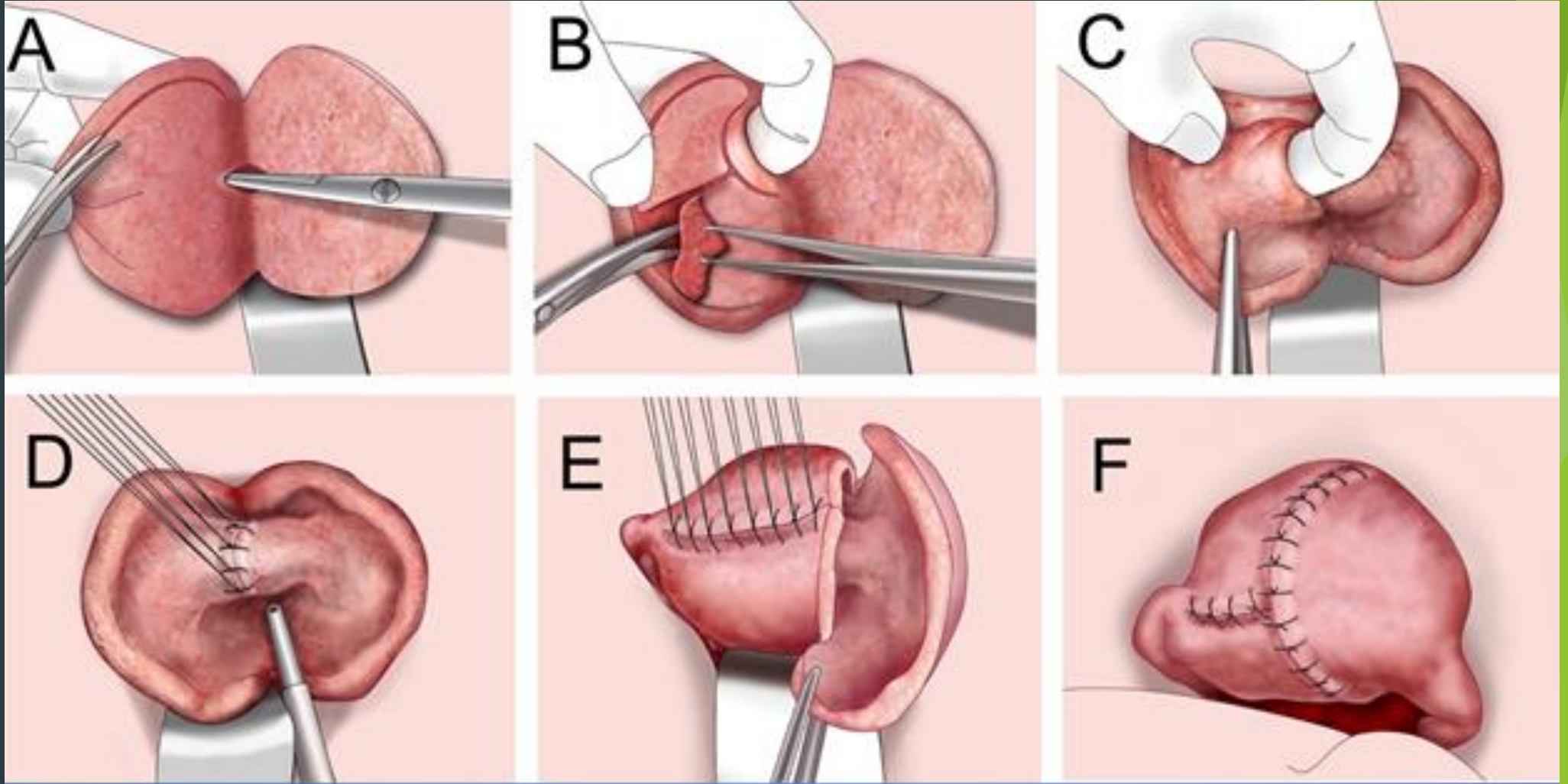
significant reduction of symptoms related to bleeding and pain

26 women who desired pregnancy, 16 could get pregnant and 14 went to term and all of them delivered a healthy baby

There were no cases of uterine rupture.

Surgical procedure to conserve the uterus for future pregnancy in patients suffering from massive adenomyosis-Osada et al. reprod biomed. 2011

## Osada procedure :



A prospective study

**dr.saremi**

103 Iranian women with  
symptomatic uterine adenomyosis.

Procedure: resection of lesions with a thin ( $\leq 0.5$  cm) margin  
(wedge-shaped removal) after sagittal incision in the uterine  
body. Reconstruction was performed in layers

1-70 patients who attempted pregnancy, 30% achieved a  
clinical pregnancy and 16 resulted in a full-term live birth.

2-Dysmenorrhea and menorrhagia were reduced post-surgery.

3-one patient had a recurrence of adenomyosis

The mainly difference between this technique and that of  
Nishida et al. is the non-opening of the endometrium.

Treatment of adenomyomectomy in women with sever uterine adenomyosis using a novel  
technique.saremi etal.reprod biomed 2014

the optimum wall thickness

Maintaining a healthy uterus is of paramount importance in conservative surgeries for adenomyosis.

the optimum wall thickness should be from 9 to 15 mm to allow conception and prevent uterine rupture during pregnancy.

Otsubo et al. aust N Z J obstet gynecol 2016



# Hystroscopic treatment of adenomyosis

not first line treatment modality  
should be performed in selected cases

## 1- office hystroscopy

- to enucleate superficial focal adenomyosis
- to evacuate cystic hemorrhagic lesion less than 1.5 cm with sono guide

## 2- resectoscopy

- superficial adenomyosis > 1.5 cm
- diffuse superficial adenomyosis in whom not desiring future pregnancy

lack of cleavage plane can make the procedure challenging

the role of hystroscopy in the diagnosis and treatment of adenomyosis-Spiezio sardo  
etal.biomedresearch international 2017

Most studies reported improvement in dysmenorrhea and dyspareunia.

After complete excision:

25% to 80% of patients: reduction in menorrhagia

50% to 94.7% had pain improvement

After incomplete excision:

40% improvement in menorrhagia & 55% to 94% had pain improvement.

nonexcisional techniques :

57% to 86.8%

of patients had pain control

81.3% to 98.4% had bleeding control

Recurrences: as early as a year after surgery

Recurrences: as early as a year after surgery

Less recurrences were found when medical treatment was started immediately after surgery

Recurrence rate is estimated:

9% in the complete excision technique

19% in the partial excision

32.5% in the nonexcisional techniques

ART methods show increased pregnancy rates compared with natural cycles after an operative intervention for adenomyosis

Vercellini et al., Hum Reprod 2014 ; Benagiano et al., 2015

# UTERINE RUPTURE RATE

- ▶ non-scarred uterus 0.005%
- ▶ scarred uteri 0.04%-0.02%
- ▶ vaginal births after cesarean sections further increase the risk to 0.27%-0.7%
- ▶ **A literature review**
- ▶ uterine rupture after uterine adenomyosis is 6.0%
- ▶ uterine rupture after uterine myomectomy 0.26%



## RECOMMENDED PERIOD BETWEEN ADENOMYOSIS SURGERY AND PERMISSION FOR PREGNANCY *OSADA 2019*

No reported investigation into the contraception period recommended prior to pregnancy, following surgical removal of [uterine adenomyosis](#), has been found. The postoperative field may be observed as an avascular area, when using colored Doppler imaging and contrast-enhanced [MRI](#). [The author has given permission for pregnancy to be attempted after confirming the resumption of blood flow \(loss of the avascular area\) to the postoperative field. In this area, blood flow resumed, in 92 cases \(81.4%\), within 6 months. However, when the uterine wall was largely resected, the resumption of blood flow could be delayed by >2 years \(20\).](#)

but when? how? How much? By whom?

• Live

ADENOMYOSIS SURGERY YES...  
BUT WHEN? HOW? HOW MUCH AND BY  
WHOM?

EXPERIENCE = Specialization

Consultation & Counseling = Information

Obstetrical care & communication = Team work



# Take home message

**Conservative surgical treatment for adenomyosis**  
is effective for symptom control such as menorrhagia  
and dysmenorrhea and most probably for adenomyosis-  
related infertility

treatment should be individualized  
preserving fertility and relieving symptoms

**medical treatment**

**excisional surgery**  
could be performed for refractory adenomyosis.



## Take home messages



- Signification of *diffuse* Adenomyosis ?
- *Focal* adenomyosis:
  - Marker for DIE severity
  - TVUS diagnosis ?
- Adenomyosis pathogenesis: *2 different entities ?*
  - *Diffuse:* Junction Zone
  - *Focal:* Implantation

▶ *THANKS for YOUR ATTENTION*