

Screening for Down's syndrome chromosomal defects

Dr. Sonia Eskandarion

- The traditional method of screening for Down's syndrome has been maternal age where **amniocentesis or chorionic villous sampling** is offered to women **aged 35 years or more**.
- This results in the need for an invasive test in **15-20%** of pregnant women with a detection of **less than half of the fetuses** with Down's syndrome, **because the majority of affected fetuses come from the younger age group**

A more effective method of screening is based in the combination of:

- Maternal age
- A maternal blood sample for the measurement of the placental products of free β -hCG and PAPP-A
- An ultrasound scan at 11-13 weeks:
 - to measure the collection of fluid behind the fetal neck (nuchal translucency)
 - to examine the fetal nose and palate
 - to measure the fetal heart rate
 - to assess the flow of blood across the tricuspid valve of the fetal heart and the ductus venosus

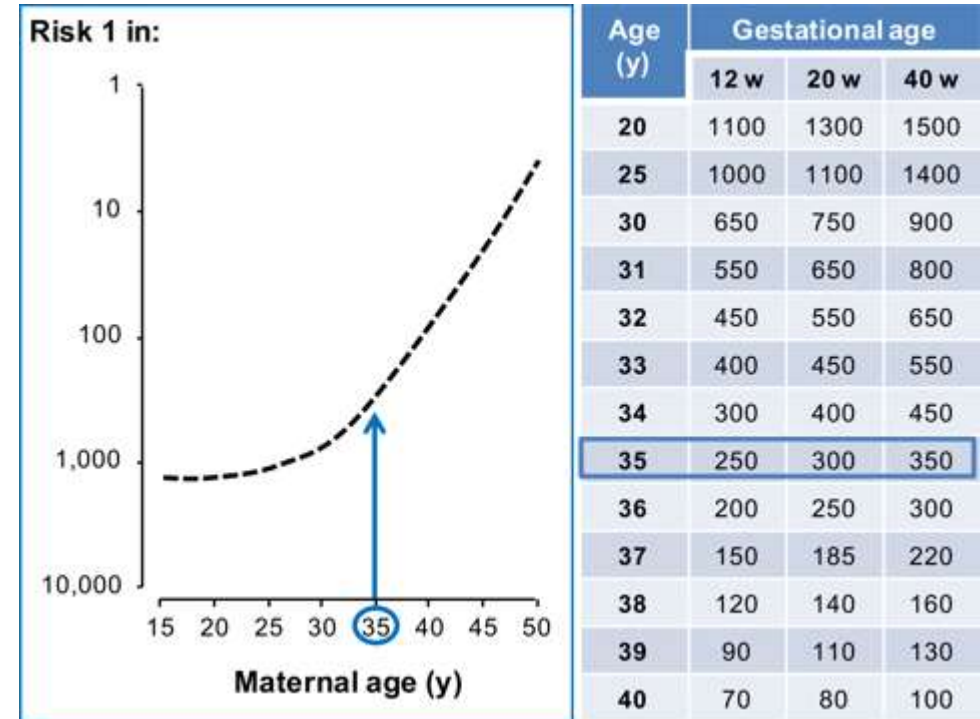
- This new method of screening reduces dramatically the number of women requiring an **invasive test** from about **20% to less than 3%** and
- at the same time increases the **detection rate of Down's syndrome** and other major chromosomal abnormalities from **less than 50% to more than 95%**

Risk for trisomy 21

Increases with maternal age.

Decreases with gestational age because about 30% of affected fetuses die between the 12th and 40th week of pregnancy.

For example, in a woman who is 35 years old the risk for trisomy 21 at the 12th week of pregnancy is 1 in 250, but the chance that she will deliver an affected baby at 40 weeks is 1 in 350.

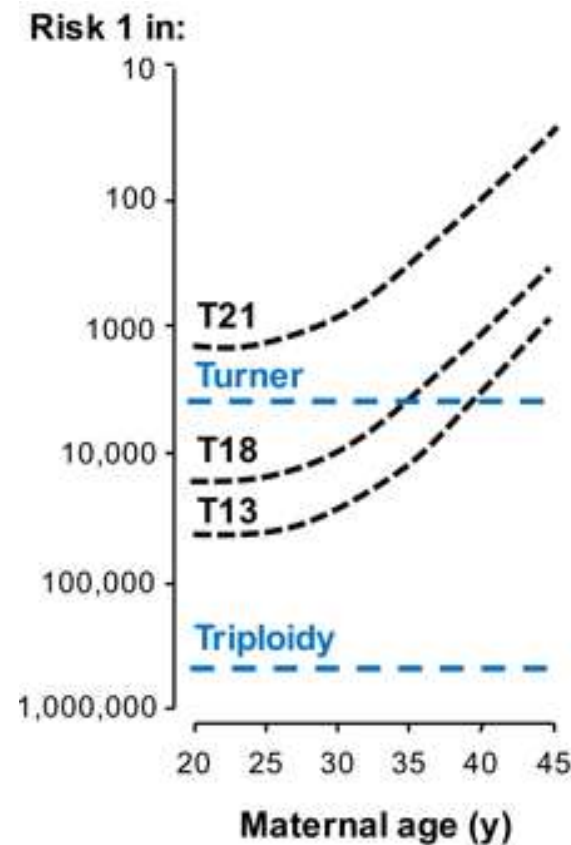


Other aneuploidies

The risk for trisomies 18 and 13 increases with maternal age and decreases with gestation. The rate of fetal death between the 12th and 40th week is about 80%.

Turner syndrome is unrelated to maternal age. The rate of fetal death between the 12th and 40th week is about 80%. The prevalence is about 1 in 1500 at 12 weeks and 1 in 4000 at 40 weeks.

Triploidy is unrelated to maternal age. The prevalence at 12 weeks is about 1 in 2000 but it is highly lethal and is very rarely observed in live births.



Age (y)	Trisomy 18		Trisomy 13	
	12 w	40 w	12 w	40 w
20	2500	18000	7800	42500
25	2200	16000	7000	37600
30	1500	10600	4600	25000
31	1300	9200	4000	22000
32	1100	7800	3400	18000
33	900	6500	2800	15000
34	700	5300	2300	12400
35	600	4200	1800	10000
36	450	3300	1400	7800
37	350	2600	1100	6000
38	270	2000	860	4700
39	210	1500	650	3500
40	160	1150	500	2700

Screening performance for trisomy 21

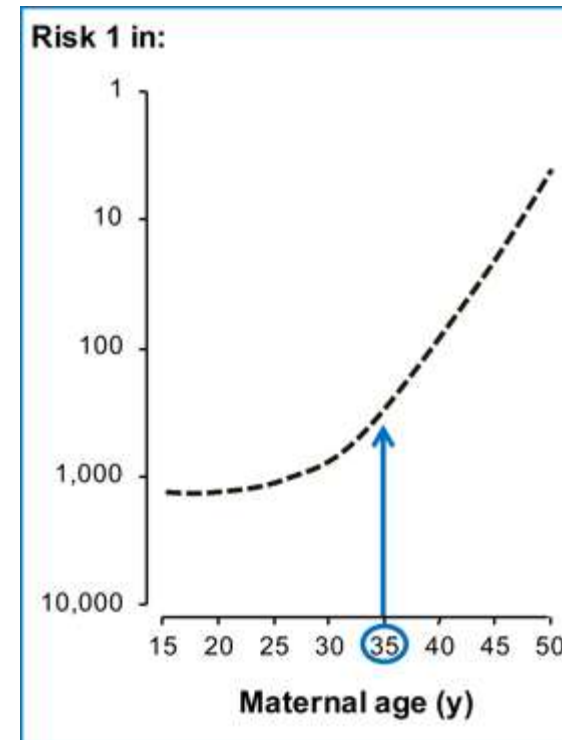
The risk for trisomy 21 increases with maternal age but because there are a lot more women in the younger age group the **majority of fetuses with trisomy 21 are in the women aged under 35 years.**

In the 1970's and 1980's screening for trisomy 21 was based on maternal age and amniocentesis or CVS was offered to those aged 35 years or older. About 5% of pregnant women were ≥ 35 years and a policy of screening based on maternal age would result in:

Invasive testing rate 5%

Detection rate of trisomy 21 30%

In most developed countries in the last 30 years the maternal age of pregnant women has increased and now about 20% of pregnancies, including 50% of fetuses with trisomy 21, are in women aged ≥ 35 years.



Maternal age ≥ 35 y

1970

5% of pregnancies
30% of cases of T21

2000

20% of pregnancies
50% of cases of T21

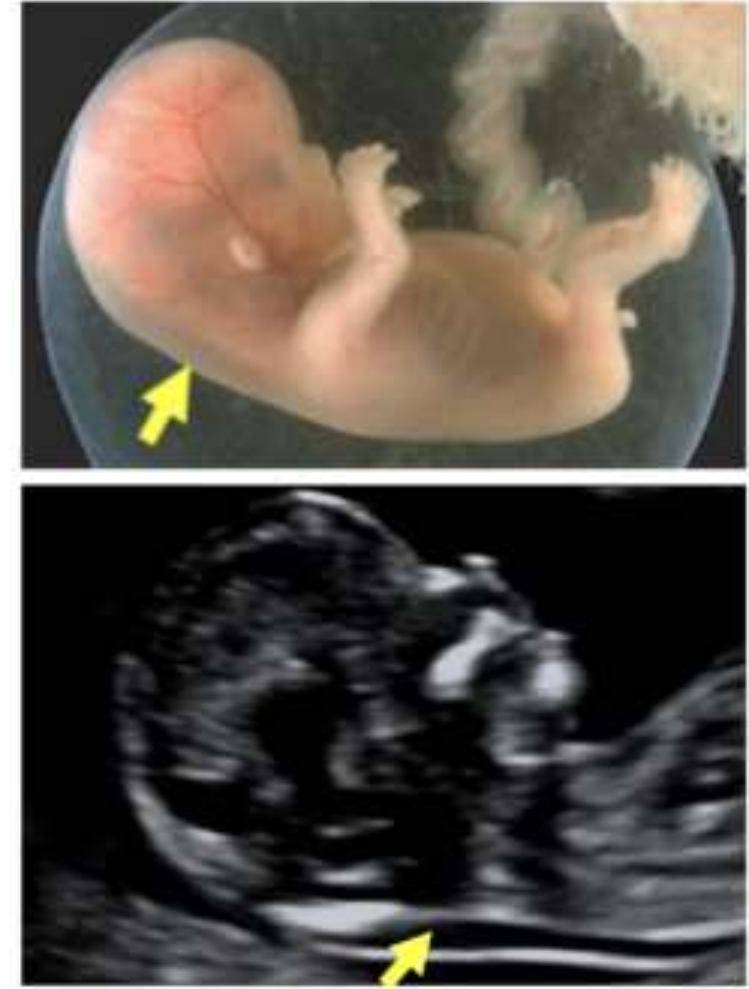Nuchal translucency

Nuchal translucency (NT) is the sonographic appearance of a **collection of fluid under the skin behind the fetal neck** in the first trimester of pregnancy.

The term translucency is used, irrespective of whether it is septated or not and whether it is confined to the neck or envelopes the whole fetus.

The incidence of chromosomal and other abnormalities is related to the **size**, rather than the appearance of NT.

During the **second trimester, the translucency usually resolves** and, in a few cases, it evolves into either nuchal edema or cystic hygromas with or without generalized hydrops.



Gestational age

The optimal gestational age for measurement of fetal NT is **11+0 to 13+6** weeks. The minimum fetal crown–rump length (CRL) should be **45 mm and the maximum 84 mm**.

The reasons for selecting 11+0 weeks as the earliest gestation are:

Screening necessitates the availability of a diagnostic test and chorionic villous sampling before this gestation is associated with transverse limb reduction defects.

Many major fetal abnormalities can be diagnosed at the NT scan, provided the minimum gestation is 11 weeks.

The reasons for selecting 13+6 weeks as the upper limit are:

To provide women with affected fetuses the option of 1st rather than 2nd trimester termination.

The incidence of abnormal accumulation of nuchal fluid in chromosomally abnormal fetuses decreases after 13 weeks.

The success rate for taking a measurement decreases after 13 weeks because the fetus becomes vertical making it more difficult to obtain the appropriate image.

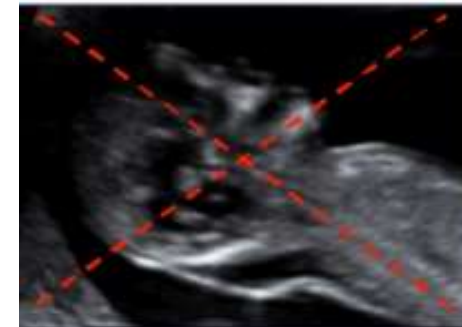
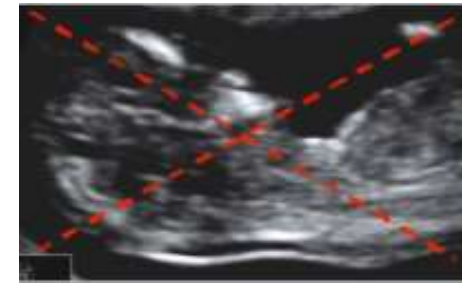
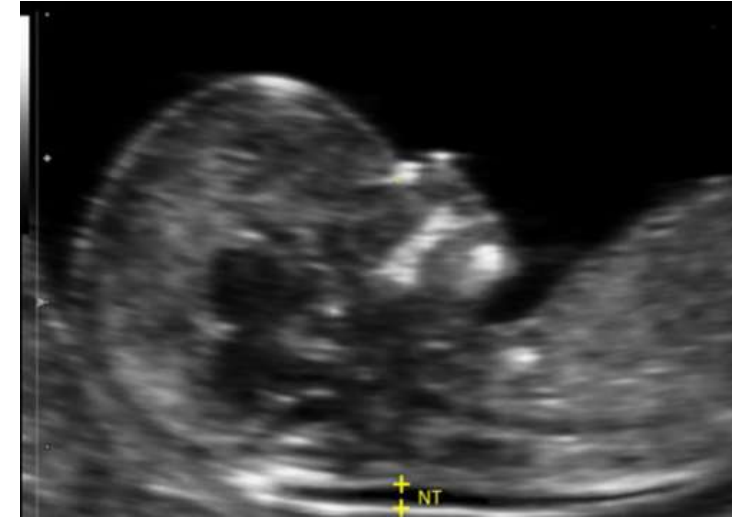Measurement

The magnification of the image should be such that **the fetal head and upper thorax occupy the whole screen.**

A mid sagittal section of the fetus must be obtained. In this section the echogenic nasal bone and rectangular palate are seen separately. Rotation of the head away from the midline results in non-visibility of the tip of the nose and the appearance of the maxillary bone as an echogenic structure between the nasal bone above and the anterior part of the palate below. With further rotation from the midline the nasal bone disappears and there is enlargement of the maxillary bone and coalescence with the palate.

The fetus should be in a neutral position, with the head in line with the spine. When the fetal neck is hyperextended the measurement can be falsely increased and when the neck is flexed, the measurement can be falsely decreased.

Care must be taken to distinguish between fetal skin and amnion.

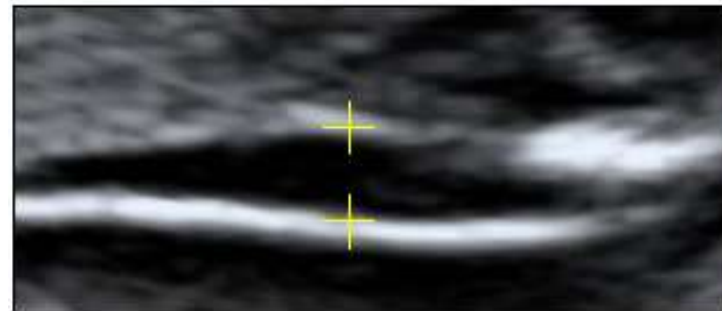
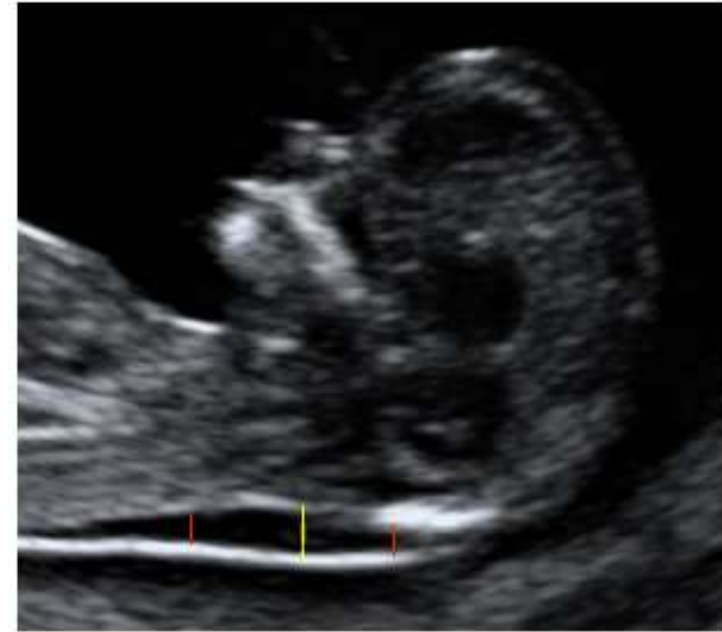

The widest part of translucency must always be measured.

Measurements should be taken with the inner border of the horizontal line of the callipers placed ON the line that defines the nuchal translucency thickness - the crossbar of the calliper should be such that it is hardly visible as it merges with the white line of the border, not in the nuchal fluid.

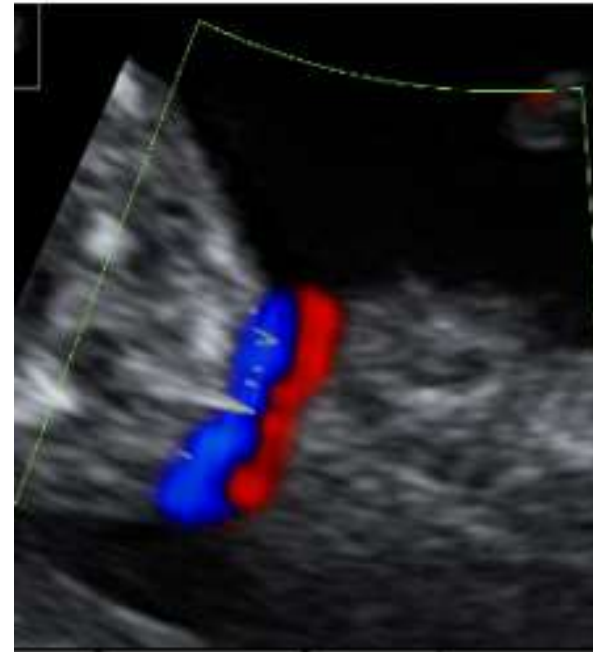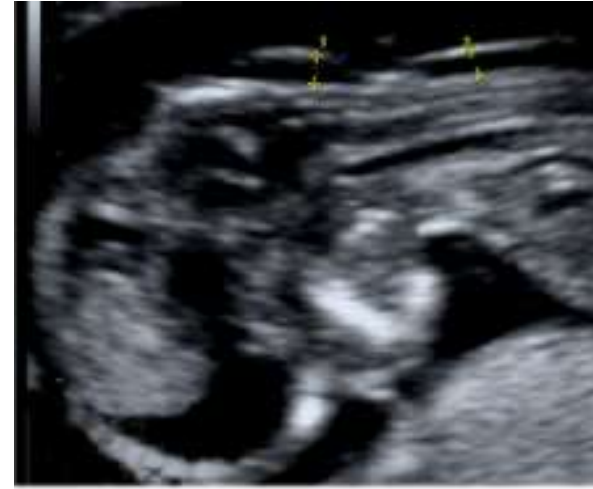In magnifying the image (pre or post freeze zoom) it is important to turn the gain down. This avoids the mistake of placing the calliper on the fuzzy edge of the line which causes an underestimate of the nuchal measurement.

During the scan more than one measurement must be taken and the maximum one that meets all the above criteria should be recorded in the database.



The umbilical cord may be round the fetal neck in about 5% of cases and this finding may produce a falsely increased NT.

In such cases, the measurements of NT above and below the cord are different and, in the calculation of risk, it is more appropriate to use the average of the two measurements.



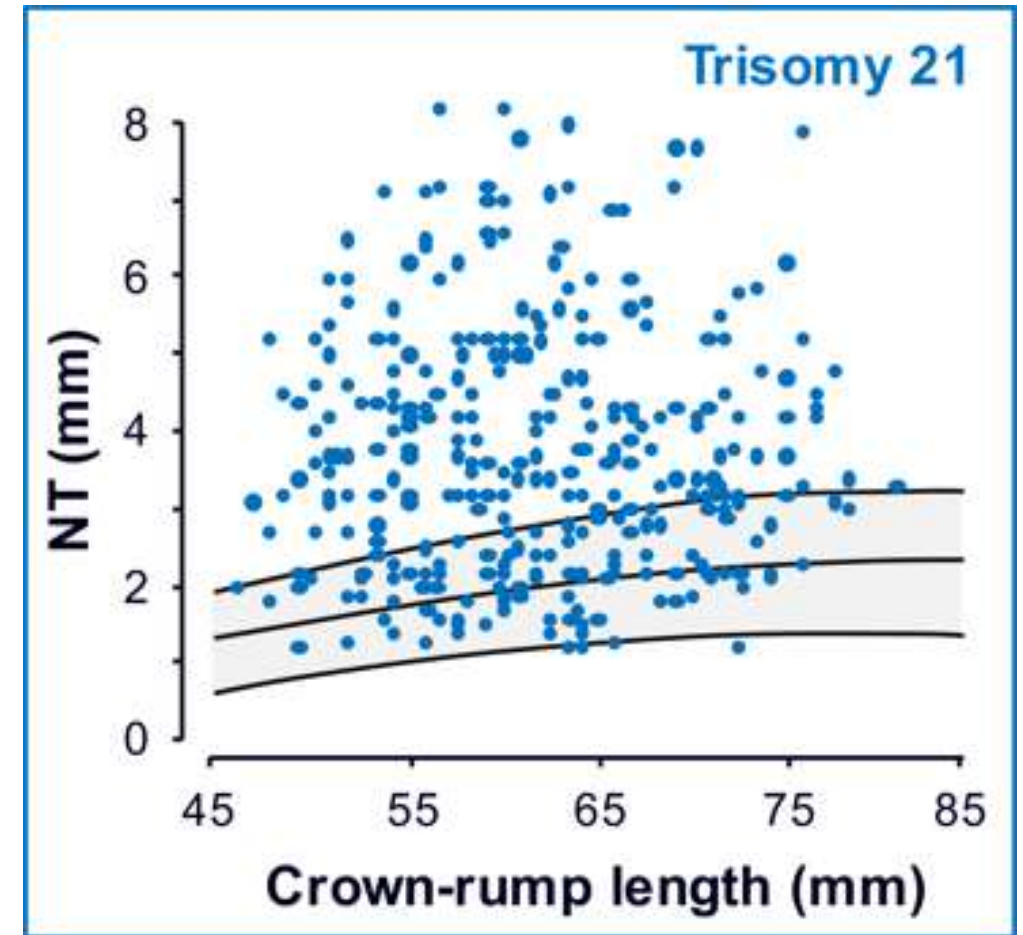
Screening for trisomy 21

In euploid fetuses the NT thickness increases with fetal CRL.

In 75-80% of trisomy 21 fetuses the NT thickness is above the 95th centile of the normal range.

In trisomy 21 fetuses there is no relationship between NT thickness and maternal age.

Maternal age can be combined with fetal NT to provide effective first-trimester screening for chromosomal abnormalities.



Serum biochemistry

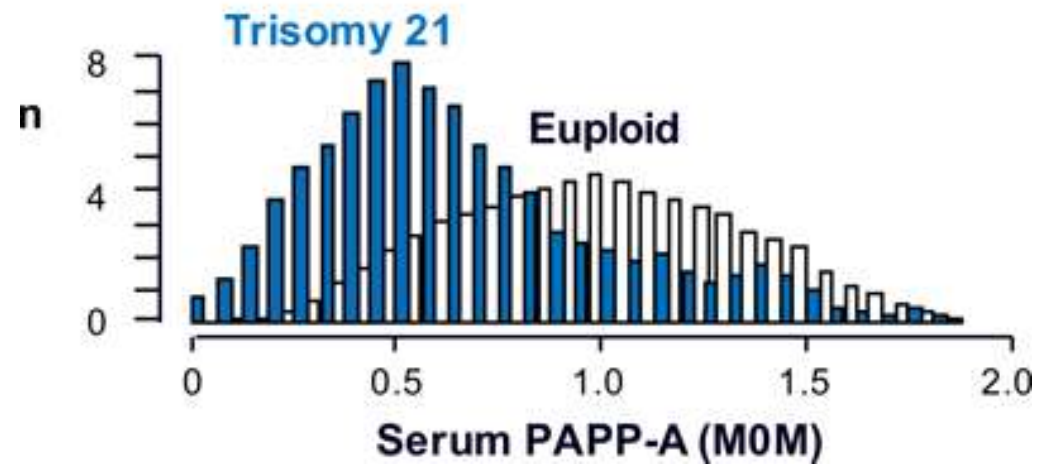
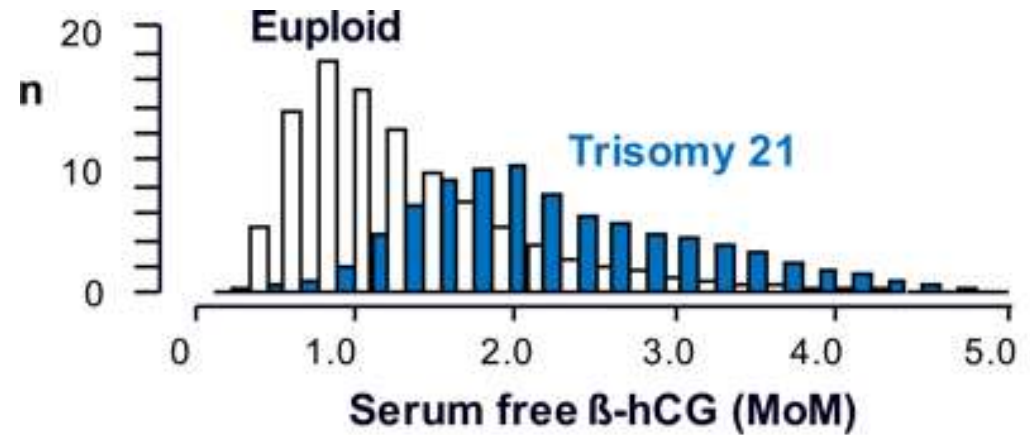
- Screening in the second trimester by maternal age and various combinations of total or free β -hCG, AFP, uE3 and Inhibin A can identify 56-71% of trisomy 21 pregnancies for a false positive rate of 5%.
- Screening in the first trimester by a combination of maternal age, fetal NT, FHR and serum free β -hCG and PAPP-A identifies about 90% of trisomy 21 pregnancies for a false positive rate of 3%.

In trisomy 21 pregnancies, maternal serum free β -hCG is about twice as high and PAPP-A is reduced to about half compared to chromosomally normal pregnancies.

Performance of screening for trisomy 21 by maternal age and serum free β -hCG and PAPP-A:

Detection rate 65%

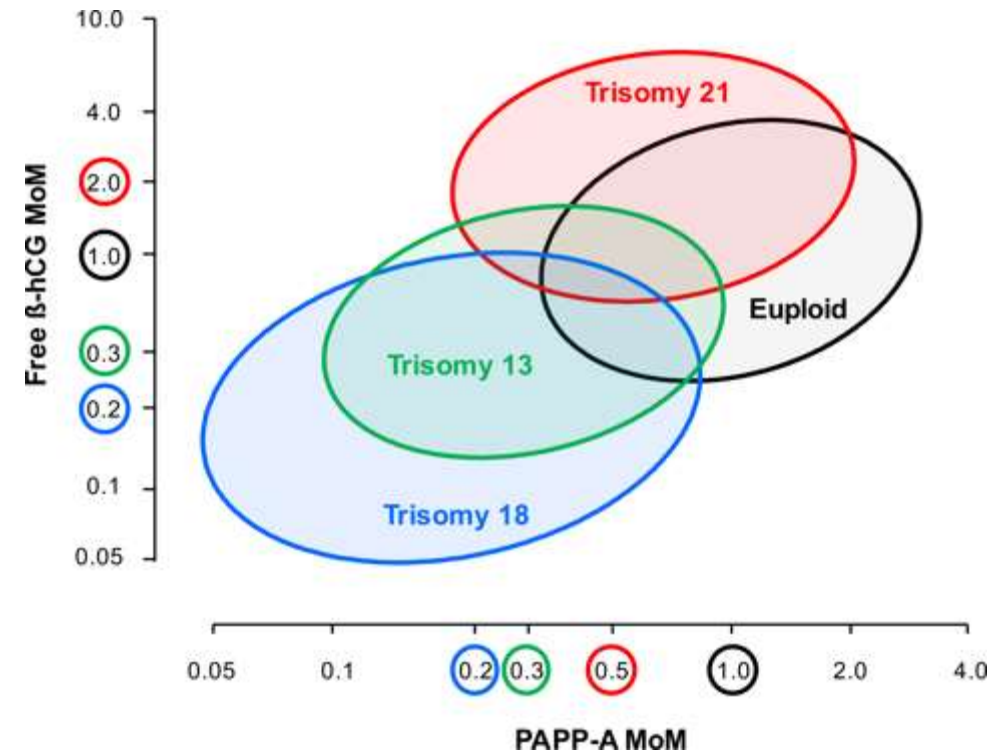
False positive rate 5%



In euploid pregnancies the average free β -hCG is 1.0 MoM and PAPP-A is 1.0 MoM.

In aneuploid pregnancies the average MoM values of free β -hCG and PAPP-A are:

	free β -hCG	PAPP-A
Trisomy 21	2.0	0.5
Trisomy 18	0.2	0.2
Trisomy 13	0.3	0.3



Nasal bone

- In the assessment of the fetal nasal bone the gestation should be 11+0 to 13+6 weeks and the CRL 45-84 mm.
- The magnification of the image should be such that the head and upper thorax occupy the whole screen.
- A mid-sagittal view of the fetal profile should be obtained.
- The ultrasound transducer should be parallel to the direction of the nose and the probe must be gently tilted from one side to the other of the fetal nose.
- When these criteria are satisfied, three distinct lines should be seen at the level of the fetal nose:
 - The top line represents the skin.
 - The bottom one, which is thicker and more echogenic than the overlying skin, represents the nasal bone.
 - A third line in front of the bone and at a higher level than the skin represents the tip of the nose.
- The nasal bone is considered to be present if it is more echogenic than the overlying skin and absent if it is either not visible or its echogenicity is the same or less than that of the skin.
- Rotation of the head by about 10° away from the midline results in non-visibility of the tip of the nose and the appearance of the maxillary bone as an echogenic structure between the nasal bone above and the anterior part of the palate below. With further rotation from the midline the nasal bone disappears and there is enlargement of the maxillary bone and coalescence with the palate.

Absent nasal bone

At 11-13 weeks the nasal bone is considered to be absent in:

Euploid fetuses 1-3%

Fetuses with trisomy 21 60%

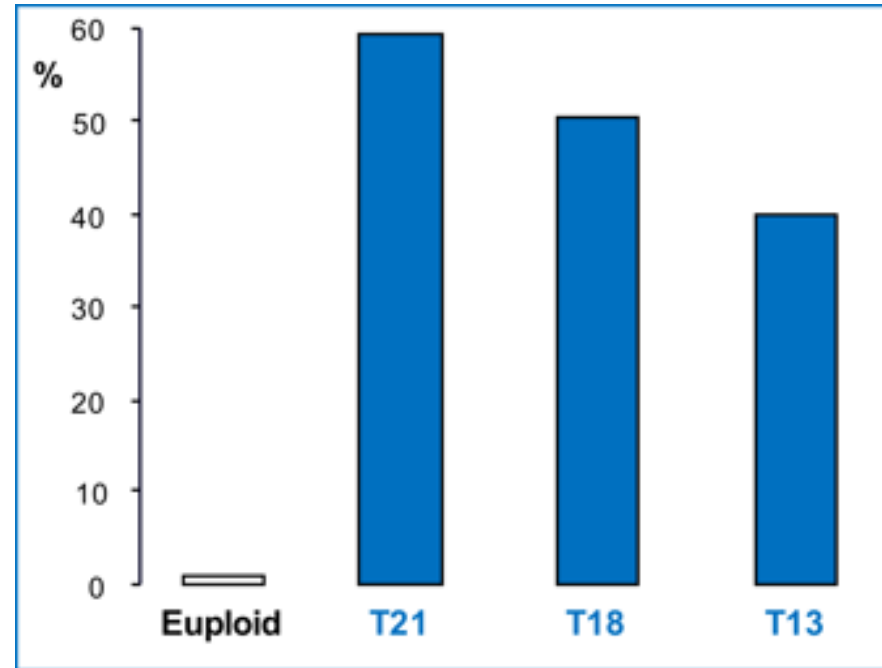
Fetuses with trisomy 18 50%

Fetuses with trisomy 13 40%

Absence of the nasal bone is more common if:

The gestation is 11 than 13 weeks.

The fetal nuchal translucency is high.



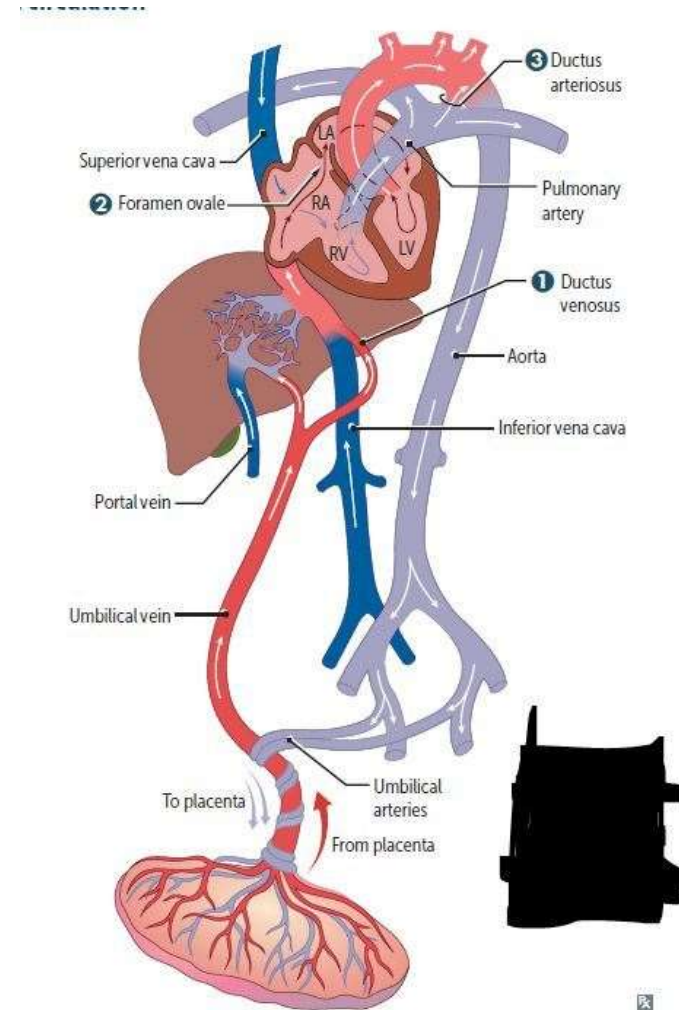
Ductus venosus flow:

The ductus venosus is a short vessel connecting the **umbilical vein to the inferior vena cava**

The ductus venosus plays a critical role in preferentially shunting oxygenated blood to the fetal brain.

About 80% of oxygenated blood from the placenta bypasses the liver and is directed to the heart. It enters the right atrium and then the left atrium through the foramen ovale. From the left atrium the blood passes into the left ventricle and then the aorta.

The ductus venosus usually closes within a few minutes after birth but this may take longer in preterm neonates.



Blood flow in the ductus has a characteristic waveform with:

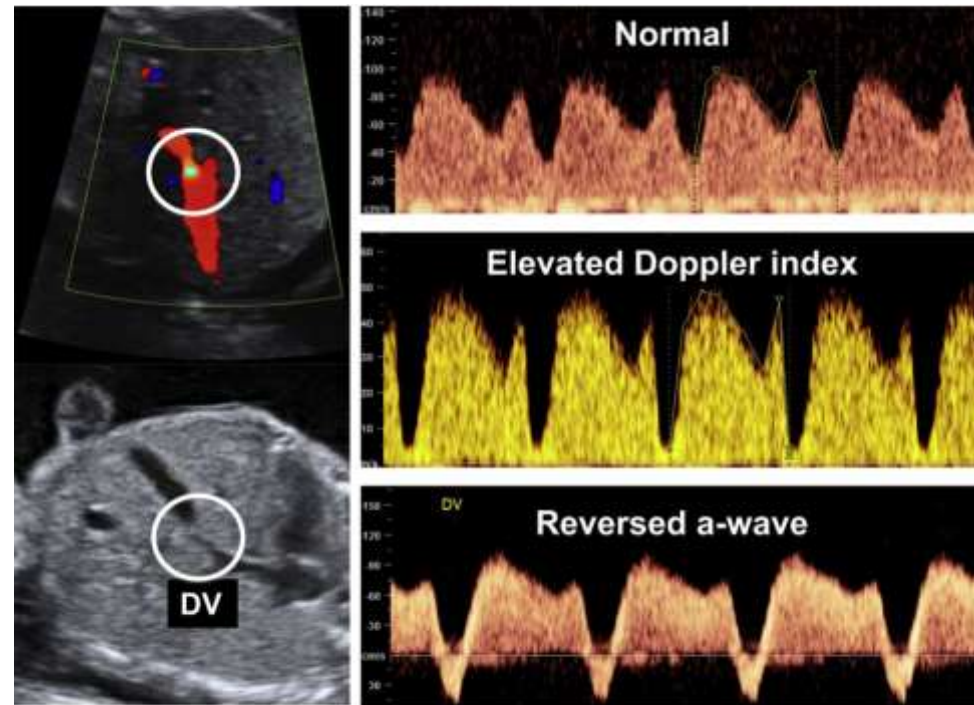
High velocity during ventricular systole (S-wave) and diastole (D-wave).

Forward flow during atrial contraction (a-wave).

Qualitative assessment of the ductus venosus blood flow is based on the appearance of **the a-wave**:

Positive or absent (normal).

Reversed (abnormal).



- At 11-13 weeks **reversed a-wave** is found in about:
 - Euploid fetuses 3%
 - Fetuses with trisomy 21 65%
 - Fetuses with trisomy 18 55%
 - Fetuses with trisomy 13 55%
-
- Reversed a-wave is more common if:
 - The gestation is 11 than 13 weeks.
 - The fetal nuchal translucency is high.
 - The maternal serum PAPP-A is low.
 - The mother is Black.
-
- Reversed a-wave is associated with increased risk for:
 - Chromosomal abnormalities
 - Cardiac defects
 - Fetal death
 - However, in about 80% of cases with reversed a-wave the pregnancy outcome is normal.

Tricuspid flow

- Tricuspid regurgitation
- At 11-13 weeks tricuspid regurgitation is found in about:
 - Euploid fetuses 1%
 - Fetuses with trisomy 21 55%
 - Fetuses with trisomy 18 30%
 - Fetuses with trisomy 13 30%
- Tricuspid regurgitation is more common if:
 - The gestation is 11 than 13 weeks.
 - The fetal nuchal translucency is high.

- Trisomy 21: Nasal hypoplasia, increased prenasal and nuchal fold thickness, cardiac defects, intracardiac echogenic foci, duodenal atresia and echogenic bowel, mild hydronephrosis, shortening of the femur, sandal gap and clinodactyly or mid-phalanx hypoplasia of the fifth finger.
- Trisomy 18: Strawberry-shaped head, choroid plexus cysts, absent corpus callosum, enlarged cisterna magna, facial cleft, micrognathia, nuchal edema, heart defects, diaphragmatic hernia, esophageal atresia, exomphalos, single umbilical artery, renal abnormalities, echogenic bowel, myelomeningocele, growth restriction and shortening of the limbs, radial aplasia, overlapping fingers and talipes or rocker bottom feet.
- Trisomy 13: Holoprosencephaly, microcephaly, facial abnormalities, cardiac abnormalities, enlarged and echogenic kidneys, exomphalos and post axial polydactyly.

- **Analysis of cfDNA in maternal blood** can detect about 99% of fetuses with trisomy 21 and 98% of fetuses with trisomies 18 or 13 at a false positive rate (FPR) of 0.1-0.2%. Therefore, in singleton pregnancies the performance of screening for these trisomies by cfDNA testing is superior, both in terms of higher detection rate and substantially lower FPR, to that of all other methods combining maternal age, first- or second-trimester ultrasound findings and first- or second-trimester serum biochemical analysis.
- In twin pregnancies performance of screening for trisomy 21 is encouraging but the number of cases reported is small.

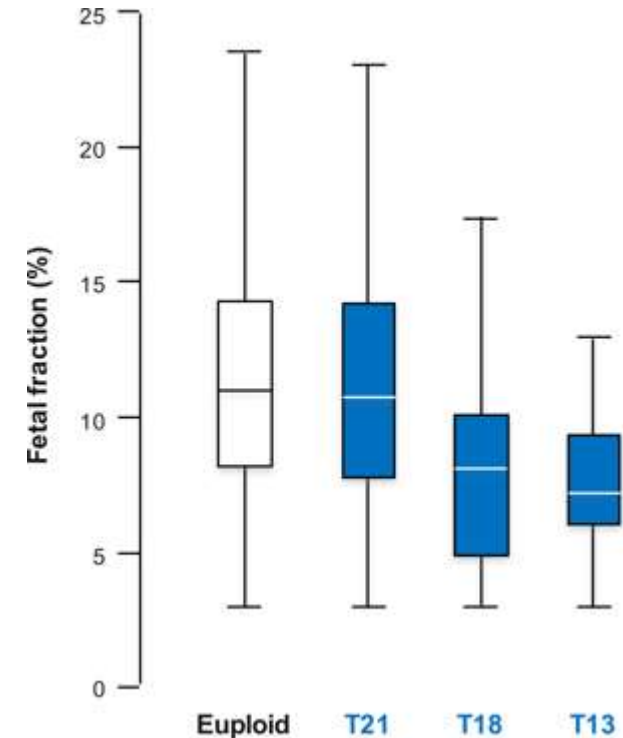
Failure to obtain result

In 1-5% of singleton pregnancies, and in a higher proportion in twin pregnancies, no result is given from the cfDNA test after first sampling. Repeat testing provides a result in 60-70% of cases.

The main reason for failed result is low fetal fraction (low proportion of fetal to total cfDNA in maternal blood).

The main determinants of low fetal fraction are maternal obesity and small placental mass.

In trisomies 18 and 13, but not in trisomy 21, the fetal fraction is lower and the rate of failed cfDNA test is higher than in normal pregnancies. Consequently, pregnancies with a failed test can be considered as being at increased risk for trisomies 18 and 13, but not for trisomy 21.



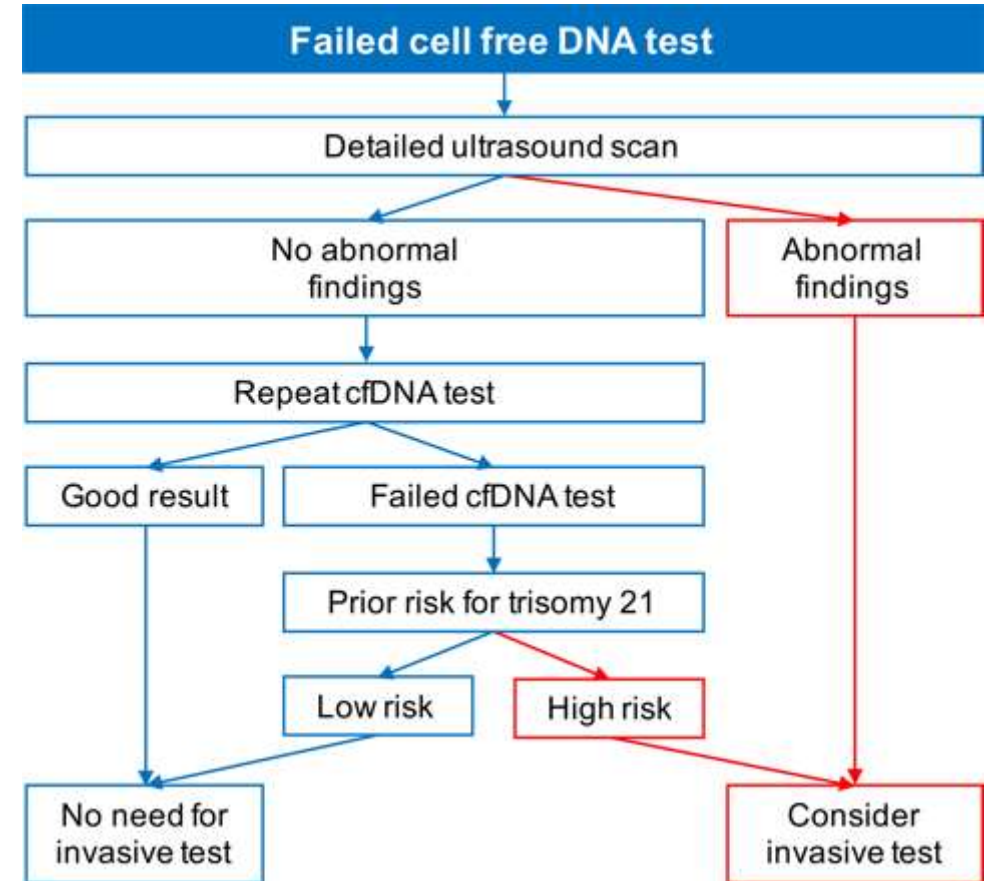
Management of failed result

The management of pregnancies with failed cfDNA test should essentially depend on the findings of a detailed scan for features of trisomies 18 and 13 and the prior risk for trisomy 21.

If there are no features of trisomies 18 or 13 and the prior risk for trisomy 21 is low the preferred option would be to repeat the cfDNA test. Even if the second cfDNA test fails the parents can be reassured that the fetus is unlikely to be trisomic.

If there are no abnormal ultrasound findings but the prior risk for trisomy 21 is high the preferred option would be to repeat the cfDNA test. If the second cfDNA test fails invasive testing should be considered.

If there are features of trisomies invasive testing should be considered.



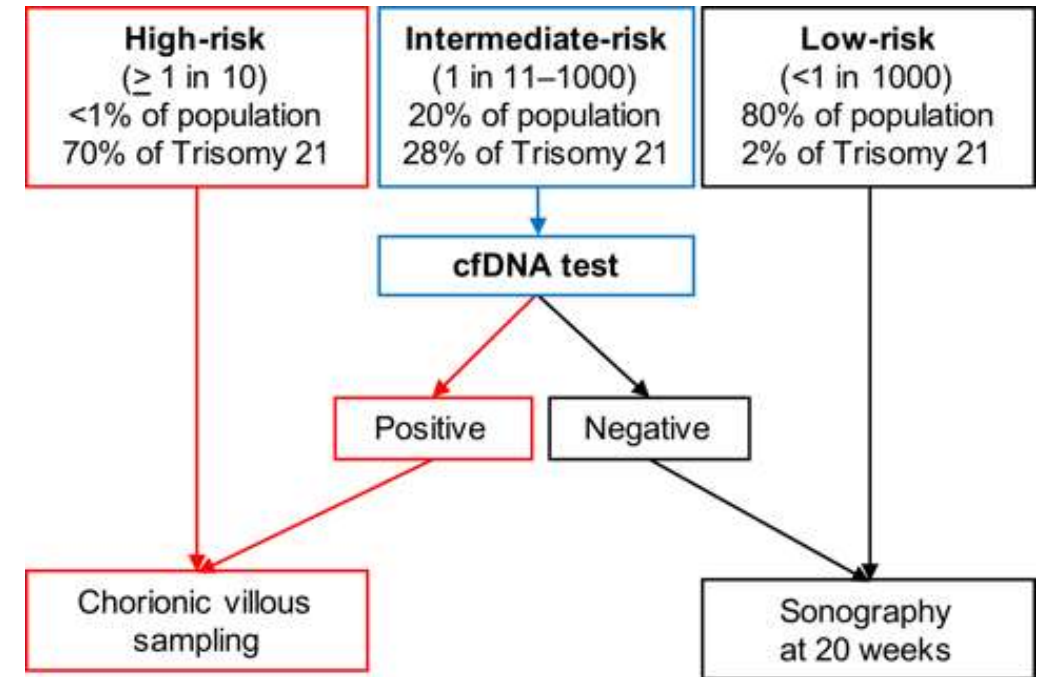
Selection based on the combined test

The results of the combined test would stratify the population into:

A very small group (<1% of the total) at very high-risk for trisomies 21, 18 or 13 (>1 in 10) that would best be managed by invasive testing because this group contains many trisomies and other chromosomal abnormalities.

A very large group (about 80% of the total) at very low risk (<1 in 1000) that contains very few of the trisomies and may not require any further tests.

An intermediate-risk group that would have cfDNA testing followed by invasive testing for those with a screen positive result.



- The exact risk cut-off that defines the intermediate- and low-risk groups will depend on the cost of cfDNA testing and therefore the proportion of the population that can be offered this test:
- At a risk cut-off of 1 in 100, 5% of the population would have cfDNA testing and 90% of all fetuses with trisomy 21 would be detected.
- At a risk cut-off of 1 in 500, 15% of the population would have cfDNA testing and 95% of all fetuses with trisomy 21 would be detected.
- At a risk cut-off of 1 in 1000, 20% of the population would have cfDNA testing and 98% of all fetuses with trisomy 21 would be detected.

Implications of high NT

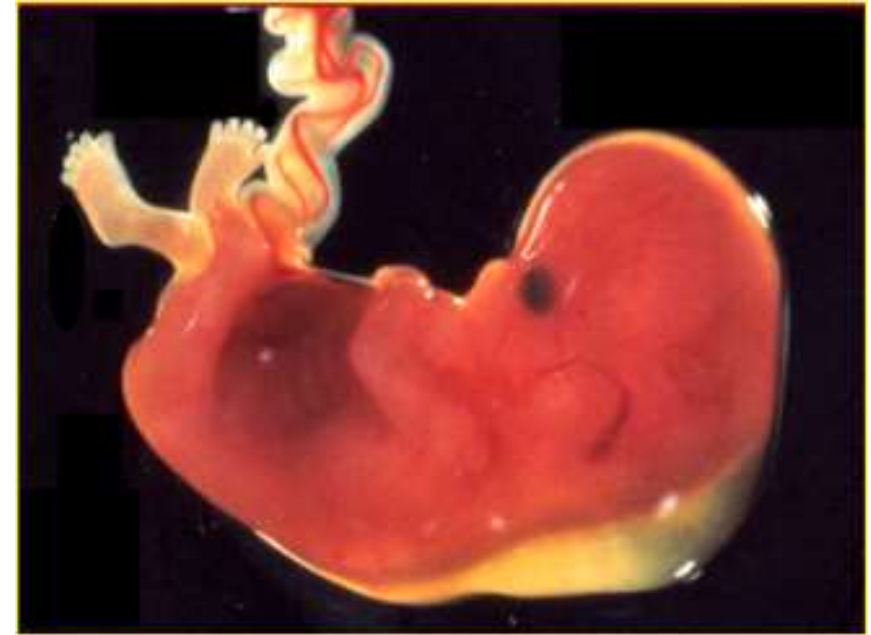Increased fetal NT thickness is associated with:

Trisomy 21 and other major chromosomal abnormalities.

More than 50 fetal defects and genetic syndromes.

Fetal death.

However, in the majority of cases the NT resolves and the babies are born healthy.



Pathophysiology

- Increased fetal NT is associated with a heterogeneous group of conditions suggesting that there may not be a single underlying mechanism for the collection of fluid under the skin of the fetal neck
- Possible mechanisms of high NT include:
 - Cardiac defects / dysfunction
 - Venous congestion in the head and neck
 - Altered composition of the extracellular matrix
 - Failure of lymphatic drainage
 - Fetal anemia
 - Fetal hypoproteinemia
 - Fetal infection

- CHROMOSOMAL DEFECTS

- The prevalence of chromosomal defects increases exponentially with NT from 0.2% for those with NT between the 5th and 95th centiles to 65% for NT of 6.5 mm or more.
- In the chromosomally abnormal group, about 50% have trisomy 21, 25% have trisomy 18 or 13, 10% have Turner syndrome, 5% have Triploidy and 10% have other chromosomal defects.

-

- FETAL DEATH

- In chromosomally normal fetuses, the prevalence of fetal death increases with NT from about 1% for those with NT between the 95th and 99th centiles to about 20% for NT of 6.5 mm or more.
- The majority of fetuses that die do so by 20 weeks and they usually show progression from increased NT to severe hydrops.

-

- MAJOR DEFECTS

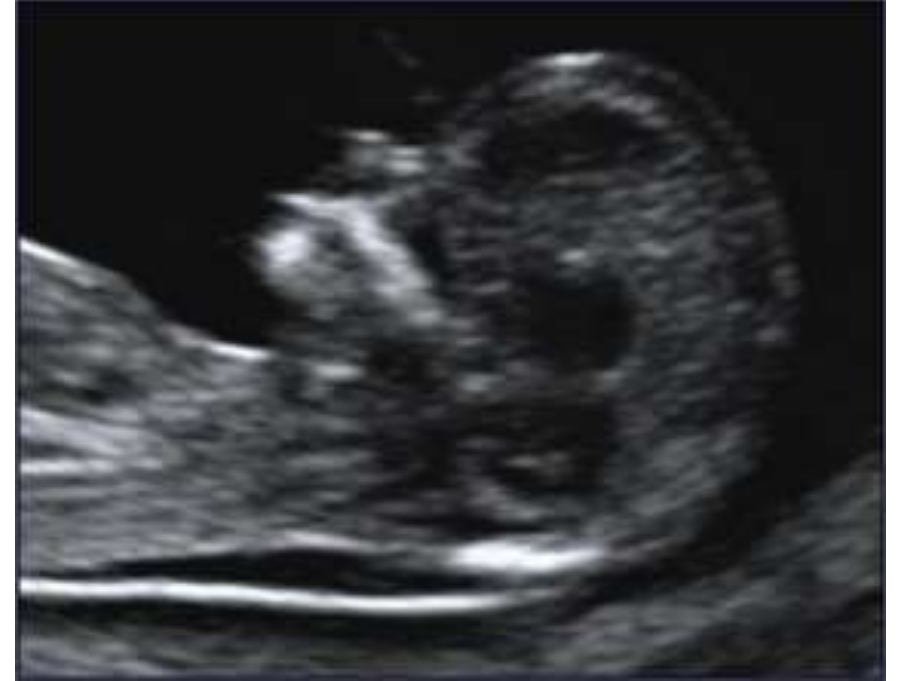- Major fetal abnormalities are defined as those requiring medical and / or surgical treatment or conditions associated with mental handicap.
- The prevalence of major fetal abnormalities in chromosomally normal fetuses increases with NT, from 1.5%, in those with NT below the 95th centile, to 2.5% for NT between the 95th and 99th centiles and exponentially to about 45% for NT of 6.5 mm or more.

Management of NT below 3.5 mm

Chorion villous sampling (CVS): the decision by the parents in favour or against fetal karyotyping will depend on the patient-specific risk for chromosomal defects, which is derived from the combination of maternal age, sonographic findings and serum free β -hCG and PAPP-A.

A detailed scan should be carried out at 11-13 weeks and again at 20 weeks in search of major abnormalities.

If no obvious abnormalities are seen the parents should be reassured that their baby is likely to be live born and develop normally. The chances that there would be any problems are not higher than in fetuses without increased NT.



Management of NT 3.5 mm or more

This is found in about 1% of pregnancies.

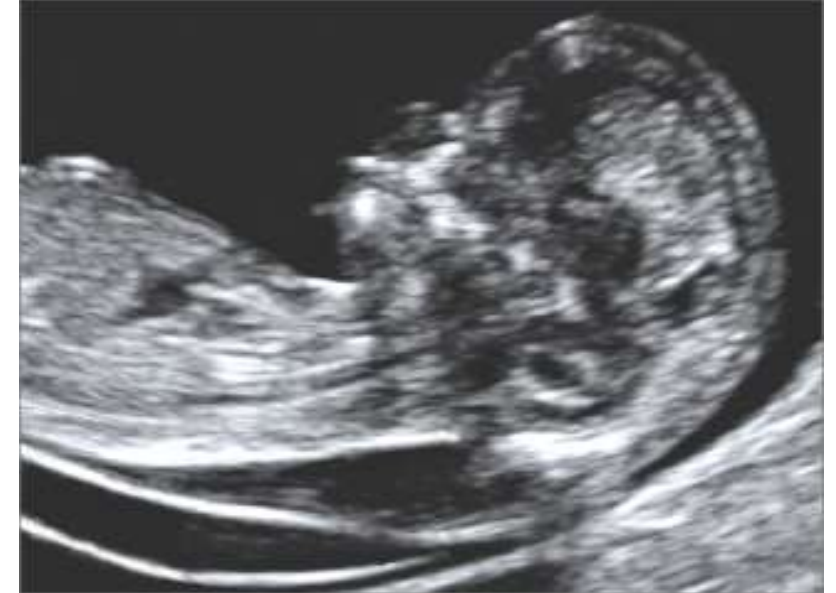The risk of chromosomal defects is very high and the first line of management of such pregnancies should be the offer of chorion villous sampling (CVS) for fetal karyotyping.

In patients with a family history of genetic syndromes that can be diagnosed by DNA analysis, the CVS sample can also be tested for these syndromes.

A detailed scan should be carried out at 11-13 weeks in search of major abnormalities and genetic syndromes.

A detailed scan is also carried out a couple of weeks later and again at 20 weeks.

If no obvious abnormalities are seen and the NT has completely resolved the parents should be reassured that their baby is likely to be live born and develop normally. The chances that the baby will have a serious abnormality or neuro-developmental delay may not be higher than in the general population.



Persistence of increased NT

If no obvious abnormalities are seen but there is persistence of increased NT at 14-16 weeks and evolution to nuchal edema or hydrops fetalis at 20-22 weeks, it is possible that there is congenital infection or a genetic syndrome:

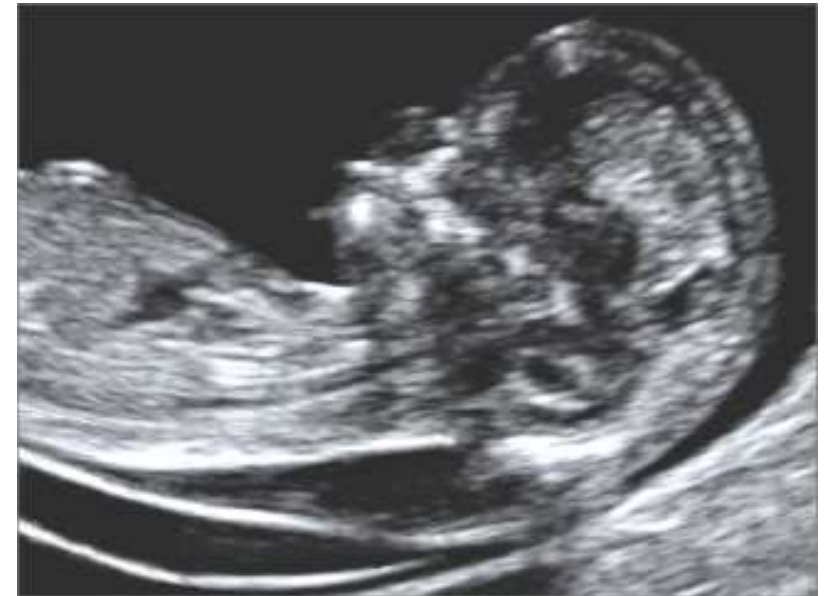Maternal blood should be tested **for toxoplasmosis, cytomegalovirus, and parvovirus B19.**

Follow-up scans should be carried out every 4 weeks to define the evolution of the edema.

Consideration should be given to DNA testing for certain genetic conditions, such as Noonan syndrome, even if there is no family history for these conditions.

There is a 10% risk of perinatal death or a live birth with a genetic syndrome that could not be diagnosed prenatally.

The risk of neurodevelopmental delay in the survivors is 3-5%.



Diagnosis of chromosomal defects

Amniocentesis and CVS

- Diagnosis of fetal chromosomal abnormalities requires invasive testing by amniocentesis or chorionic villous sampling (CVS).
- Randomized studies have demonstrated that the risk of miscarriage from CVS in the first trimester is the same as for amniocentesis in the second trimester and is about 1%.
- Amniocentesis should not be performed before 16 weeks because with early amniocentesis the rate of miscarriage is about 2% higher and the incidence of talipes equinovarus is 1.5% higher than after first-trimester CVS or second-trimester amniocentesis.
- CVS should not be performed before 11 weeks because earlier CVS is associated with fetal transverse limb abnormalities, micrognathia and microglossia.

Thanks for your attention